VIEWS

OF

THE BONES AND MUSCLES,

WITH

CONCISE EXPLANATIONS.

Robt Bickersteth
1803

VIEWS

OF THE

BONES AND MUSCLES,

WITH

CONCISE EXPLANATIONS.

SELECTED

FOR THE USE OF STUDENTS ATTENDING

PRACTICAL ANATOMY.

BY ANDREW FYFE.

EDINBURGH:

PRINTED BY J. PILLANS & SONS.
SOLD BY A. GUTHRIE, SOUTH BRIDGE-STREET;
AND
T. KAY, T. COX, T. N. LONGMAN AND O. REES, LONDON.

1803.

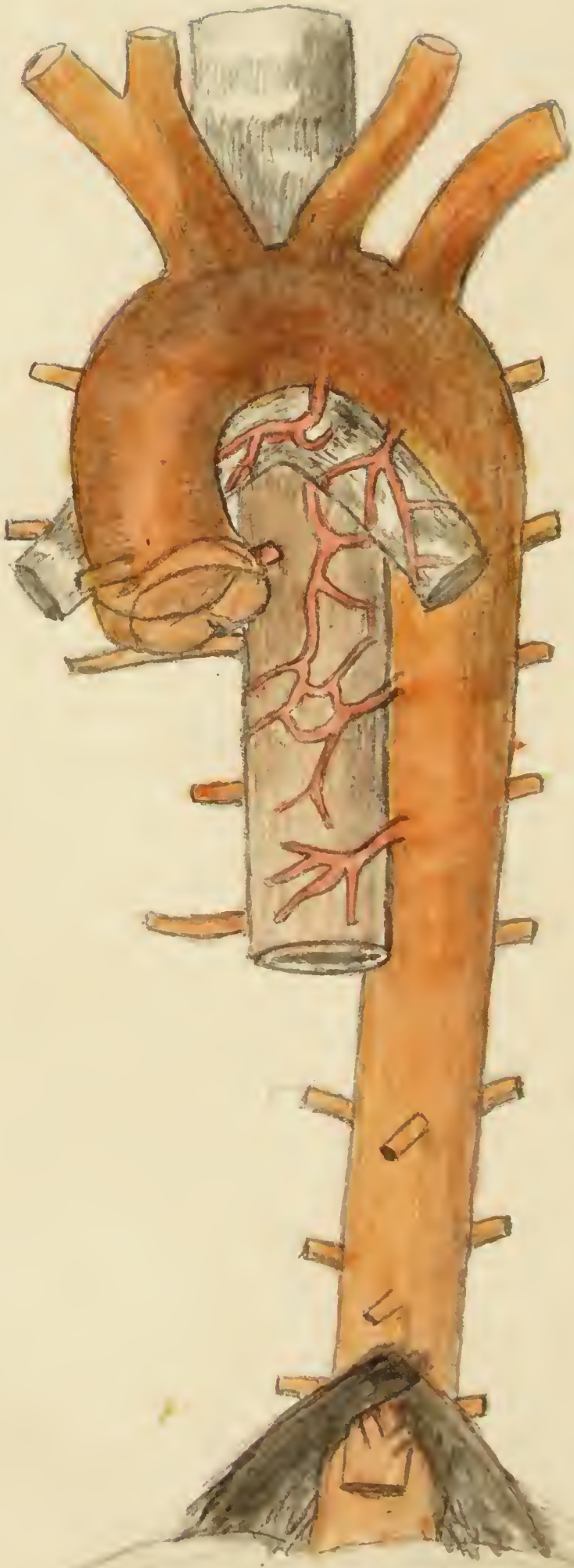

1 Common Carotid
2 Internal Carotid
3 External Carotid
4 Superior Thyroid
5 Superior Laryngeal
6 Superficial branch which gives off twigs to the sterno hyoid omohyoid & hyothyroid muscles
7 Thyroid branches
8 Lingual artery
9 Hyoid branch
10 Branch to the sterno masto-
[illegible] buccal or external maxillary
[illegible] ending palatine artery
[illegible] ery of the tonsil
[illegible] ach to the Masseter

16 Submental artery
17 Coronary of the Upper lip
18 Do of the lower lip
19 Superficial labial
+19 occipital
20 posterior auricular
21 branch of the Parotid gland
22 Do Do Do
23 Transverse artery of the face
24 Muscular branch
25 external maxillary
[illegible] Superficial Temporal

TAB. I.

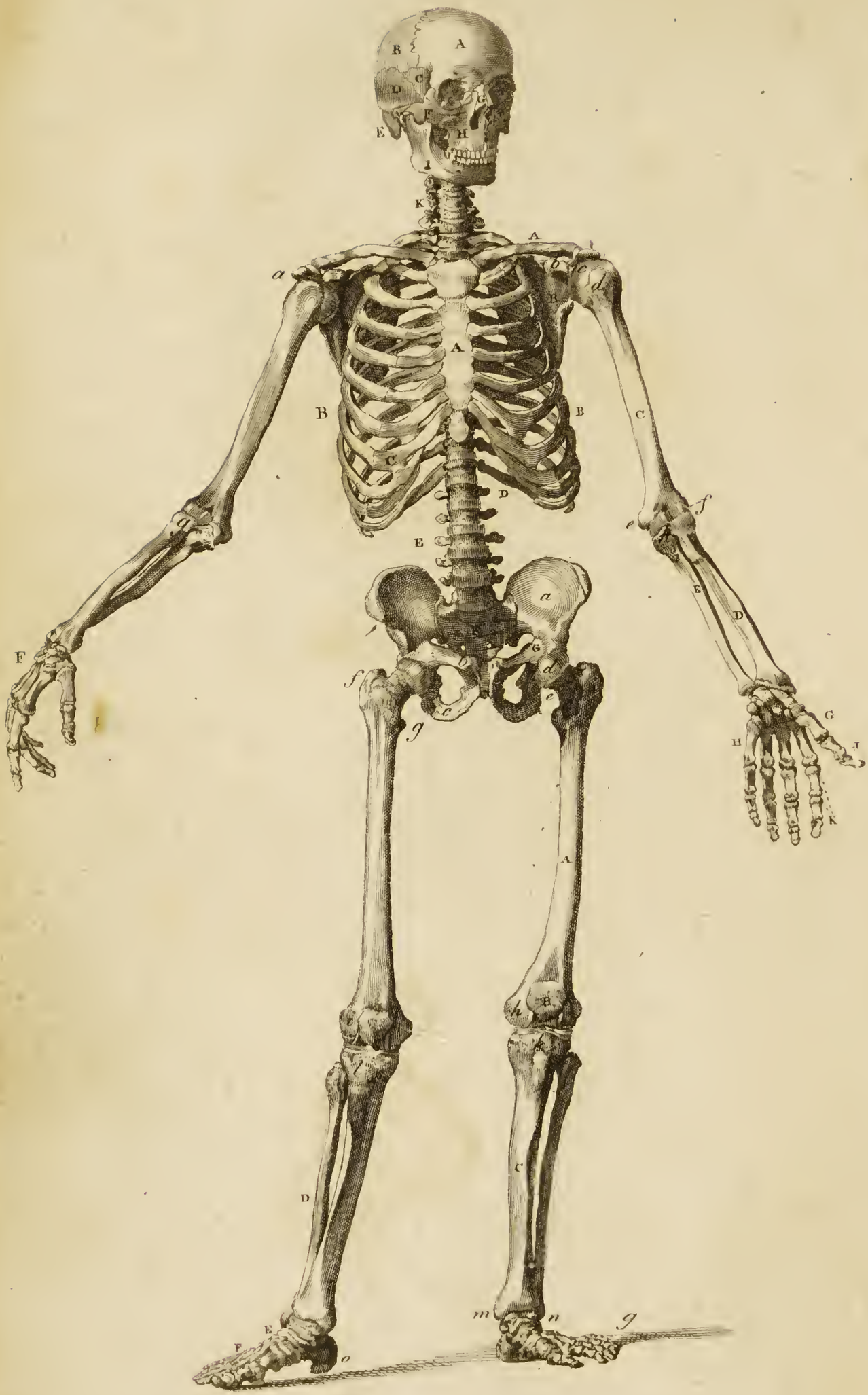

TABLE I.

REPRESENTS a Front View of the MALE SKELETON, with ſome of the CARTILAGES and LIGAMENTS which connect the BONES to each other.

HEAD and NECK.

A, The frontal bone.
B, The parietal bone.
C, Temporal proceſs of the ſphenoid bone.
D, Squamous part of the temporal bone.
E, Maſtoid proceſs of that bone.
F, The malar, or cheek-bone.
G, The naſal bone, behind which is the naſal proceſs of,
H, The ſuperior maxillary bone.
I, The lower jaw.
K, The cervical vertebræ, with their intermediate cartilages and tranſverſe proceſſes.

TRUNK.

A, The ſternum.
B, The ſeventh, or laſt true rib.
C, The cartilages of the ribs.
D, The twelfth, or laſt falſe rib.
E, The lumbar vertebræ, with their intervertebral cartilages and tranſverſe proceſſes.
F, The os ſacrum.
G, The os innominatum, compoſed of,
a, The os ilium,
b, The os pubis,
c, The os iſchium.

UPPER

TABLE I. CONTINUED.

Upper Extremity.

A, The clavicle.

B, Inner ſurface of the ſcapula.

a, The acromion of the ſcapula.

b, The coracoid proceſs of that bone.

C, The os humeri.

c, The head, or ball of the os humeri, articulated with the glenoid cavity of the ſcapula.

d, Internal tubercle of the os humeri, and farther out, the groove for lodging the tendon of the long head of the biceps muſcle.

e, The inner, and,

f, The outer condyle of the os humeri. Between *e* and *f*, the hollow for lodging the coronoid proceſs of the ulna in the flexion of the fore-arm.

D, The radius.

g, The head of the radius.

E, The ulna.

h, The coronoid proceſs of the ulna.

F, The bones of the carpus.

G, The metacarpal bone of the thumb.

H, The metacarpal bones of the fingers.

I, The two bones of the thumb.

K, The three phalanges of the fingers.

Under Extremity.

A, The os femoris.

d, The ball, or head of this bone, lodged in the acetabulum.

e, The cervix of the bone.

f, The large trochanter.

g, The ſmall trochanter.

f, The

TABLE I. CONTINUED.

h, The inner condyle.

i, The outer condyle.

B, The patella, placed upon the trochlea of the os femoris.

C, The tibia.

k, The head of the tibia, between which and the condyles of the os femoris, the ſemilunar cartilages appear.

l, The tubercle of the tibia.

m, The malleolus internus.

D, The fibula, the upper end of which is connected with the tibia.

n, The malleolus externus.

E, The bones of the tarſus.

o, The projection of the os calcis.

F, The metatarſal bones.

G, The phalanges of the toes.

TAB. 11.


A
b
C
B
D
E
G
T
K
A
b
c
a
f
B
V
V
C
g
h
k
n
g
Q
E
l
c
R
b
m
k
G
F
H
I
d
F
S
K
A
f
g
l
C
k
m
D
p
E
F
n
o

TABLE II.

REPRESENTS a Back View of the MALE SKELETON, with ſome of the CARTILAGES and LIGAMENTS which connect the BONES to each other.

HEAD and TRUNK.

A, The parietal bone.
a, The ſagittal ſuture, and parietal hole.
B, The occipital bone.
b, *b*, The lambdoid ſuture.
C, The joining of the temporal and parietal bones.
D, The cheek-bone.
E, F, The inner or back-part of the jaws, with the teeth.
G, The firſt cervical vertebra.
H, The ſecond cervical vertebra.
I, The ſeventh cervical vertebra.
c, The ſpinous proceſſes of the cervical vertebræ.
K, The firſt dorſal vertebra.
L, The twelfth dorſal vertebra.
d, The ſpinous proceſſes of the dorſal vertebræ.
e, Their tranſverſe proceſſes.
M, The firſt lumbar vertebra.
N, The fifth lumbar vertebra.
f, Their ſpinous, and,
g, Their tranverſe proceſſes.
O, The os ſacrum.
h, The uppermoſt ſpinous proceſs. Farther out are ſeen the ſuperior oblique proceſſes of this bone, joined to the inferior oblique of the laſt lumbar vertebra.

i, *i*, The

i, *i*, The lateral parts of the os ſacrum, joined to the oſſa innominata. Between *i* and O, the poſterior foramina of the os ſacrum.

k, An opening in the under and back part of this bone, covered in the ſubject by a ligamentous membrane.

P, The os coccygis, joined by its ſhoulders to the os ſacrum at the lower part of the opening *k*.

Q The os ilium.

R, The os pubis.

S, The os iſchium.

T, U, The ſeven true ribs.

V, V, The five falſe ribs.

Superior Extremity.

A, The clavicle.

B, The dorſum ſcapulæ.

a, The ſpine of the ſcapula.

b, The acromion of the ſcapula.

c, A foſſa for lodging the ſupra-ſpinatus muſcle.

d, An irregular ſurface, occupied by the infra-ſpinatus muſcle.

C, The os humeri.

e, The ball of the os humeri.

f, The external tubercle of the bone.

g, The external condyle.

h, The internal condyle.

i, Cavity for lodging the olecranon of the ulna.

D, The radius.

k, The head of the radius articulated with the trochlea of the os humeri.

l, The under end of the radius, grooved by the tendons of muſcles.

E, The

TABLE II. CONTINUED.

E, The ulna.

m, The olecranon of the ulna.

n, The under end of the ulna, with its ſtyloid proceſs.

F, The bones of the carpus.

G, The metacarpal bone of the thumb.

H, The metacarpal bones of the fingers.

I, The two bones of the thumb.

K, The three phalanges of the fingers.

Inferior Extremity.

A, The os femoris.

a, Part of the ball of the os femoris.

b, The cervix of the bone.

c, The trochanter major.

d, The trochanter minor.

e, The cavity for lodging the popliteal veſſels and nerves.

f, The external condyle.

g, The internal condyle.

h, The ſemilunar cartilages.

B, The tibia.

i, The head of the tibia.

k, The malleolus internus.

C, The fibula.

l, The head of the fibula.

m, The malleolus externus.

D, The bones of the tarſus.

n, The aſtragalus.

o, The os calcis.

p, The fore-part of the tarſus.

E, The bones of the metatarſus.

F, The phalanges of the toes.

Tab. III.

Fig. 1.

Fig. 2.

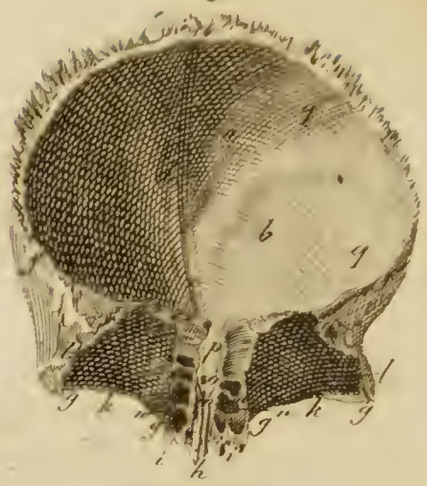

Fig. 3.

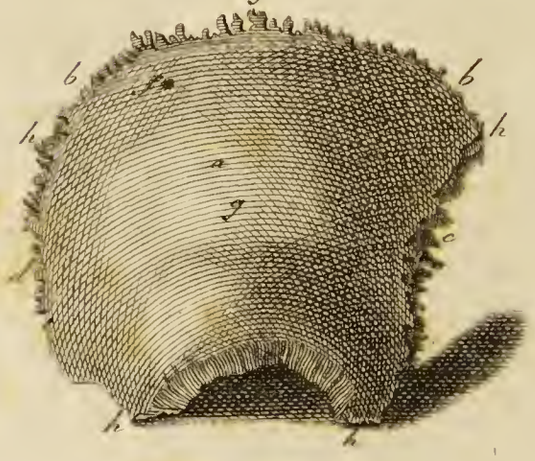

Fig. 4.

Fig. 5.

Fig. 6.

Fig. 7.



Fig. 8.

Fig. 9.

Fig. 10.

Fig. 11.

Fig. 12.

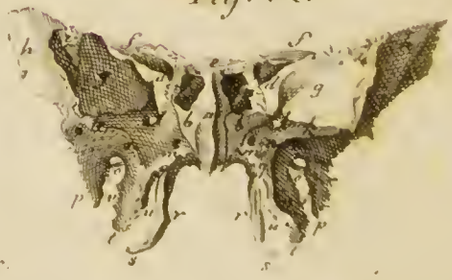

W. Archibald Sc.

TABLE III.

VIEWS of the different BONES of the CRANIUM.

FIG. 1.

The Outer Surface of the FRONTAL BONE.

a, The middle and convex part of the bone.

b, Part of the temporal foſſa.

c, *c*, *c*, *c*, The angular proceſſes.

d, The naſal proceſs.

e, Eminences and cavities, to which the naſal and maxillary bones are fixed.

f, *f*, The ſuperciliary arches.

g, *g*, The ſuperciliary holes.

h, *h*, The orbitar plates.

i, *i*, The lacrymal foſſæ.

k, *k*, The internal orbitar foramina.

l, *l*, Inequalities which unite this bone to the os ſphenoides.

FIG. 2.

The Inner Surface of the FRONTAL BONE.

a, The concave part of the bone.

b, The cavity which lodges the anterior lobes of the brain.

c, The frontal ſpine.

d, Furrow where the falx is fixed, and the ſuperior longitudinal ſinus is lodged.

e, Ragged edge of the bone, which aſſiſts in forming the coronal ſuture.

f, *f*, Other inequalities, which join the frontal to the ſphenoid bone.

g, *g*, *g*, *g*, Inner ſurface of the angular proceſſes.

h, The poſterior ſurface of the naſal proceſs.

i, *i*, Other inequalities, near the naſal proceſs.

k, *k*, The orbitar plates.

l, *l*, The

l, l, The lacrymal foſſæ.

m, m, Cells which correſpond with thoſe of the œthmoid bone.

n, n, The paſſages from the frontal ſinuſes.

o, The foramen cæcum.

p, The opening which receives the cribriform plate of the œthmoid bone.

q, q, Furrows which lodge the blood-veſſels of the dura mater.

FIG. 3.

External Surface of the Right PARIETAL BONE.

a, The middle convex part of the bone.

b, b, The upper ragged edge of the bone, which, when joined to its fellow, forms the ſagittal ſuture.

c, The anterior edge, which aſſiſts in forming the coronal ſuture.

d, The poſterior edge, which joins the occipital bone, and forms the lambdoid ſuture.

e, The inferior ſemilunar edge, which joins the ſquamous part of the temporal bone.

f, The parietal hole.

g, An arched ridge which gives origin to a large ſhare of the temporal muſcle.

h, h, h, h, The angles of the bone.

FIG. 4.

Internal Surface of the ſame PARIETAL BONE.

a, The middle concave part.

b, The inner ſurface of the upper edge of the bone, where the indentations are more apparent than thoſe of the outer ſide.

c, The parietal hole.

d, Anterior

d, Anterior ſerrated edge of the bone.

e, Poſterior edge, more indented than the anterior one.

f, *f*, The ſuperior angles.

g, *g*, The inferior anterior angle, where the beginning of the furrow is ſeen, which lodges the trunk of the principal artery of the dura mater.

h, *h*, The ramifications of that furrow.

i, *i*, Small furrows which lodge other arteries of the dura mater.

k, A depreſſion which lodges part of the lateral ſinus.

l, The inferior edge of the bone, conſiderably thinner than the reſt.

FIG. 5.

View of the External Surface of the OCCIPITAL BONE.

a, The ſuperior angle of the bone.

b, *b*, The ragged edge, which aſſiſts in forming the lambdoid ſuture.

c, *c*, The irregularities at the lateral and inferior parts of the bone, where it is joined to the oſſa temporum.

d, *d*, The large tranſverſe arched ridge, or ſpine. occipital prot. Compleus-

e, *e*, Muſcular prints upon the tranſverſe ridge.

f, The perpendicular ſpine.

g, The ſmaller arched ridge, croſſing the perpendicular ſpine. Splenius - rect - obliquus ſup

h, *h*, Muſcular prints above,

i, The foramen magnum.

k, *k*, The occipital condyles.

l, *l*, The poſterior condyloid foramina.

m, *m*, The inner ſide of the left, and outer ſide of the right anterior condyloid foramen.

n, *n*, Nitches which aſſiſt in forming the holes common to the occipital and temporal bones.

o, The cuneiform proceſs, marked by the attachment of muſcles.

FIG.

FIG. 6.

Internal Surface of the OCCIPITAL BONE.

a, The ſuperior angle of the bone.

b, *b*, The middle or lateral angles.

c, *c*, Eminences and cavities which aſſiſt in forming the lambdoid ſuture.

d, *d*, The ſuperior occipital foſſæ, which lodge a ſhare of the poſterior lobes of the brain.

e, *e*, The inferior occipital foſſæ, which contain part of the cerebellum.

f, *f*, The upper limb of the perpendicular ſpine, which receives the ſuperior longitudinal ſinus, and has the falx fixed to it.

g, The lower limb of that ſpine, to which the falx minor is fixed.

h, *h*, The foſſæ, which contain the lateral ſinuſes, and have the tentorium fixed to their edges.

i, *i*, The openings which form part of the foramina lacera, common to this bone and the os temporis.

k, *k*, The ſmall proceſſes which aſſiſt in forming the foramina lacera.

l, *l*, The poſterior condyloid holes.

m, The anterior condyloid hole of the right ſide.

n, The concave ſurface of the cuneiform proceſs.

o, The inequalities of the cuneiform proceſs, by which it is united with the ſphenoid bone.

p, The foramen magnum.

FIG. 7.

The Outer Surface of the TEMPORAL BONE *of the Right Side.*

a, The upper and ſquamous part of the bone.

b, The under part, which lodges a portion of the temporal muſcle.

c, That

c, That part of the bone which aſſiſts in forming the additamentum of the ſquamous ſuture.

d, The zygomatic proceſs.

e, The tranſverſe, or articular proceſs.

f, The maſtoid proceſs.

g, Small holes, for tranſmitting veſſels to the bone, or to the dura mater.

h, Meatus auditorius externus, ſurrounded by a rough margin.

i, The glenoid, or articular cavity.

k, The glenoid fiſſure, for the attachment of part of the articular ligament.

l, The vaginal proceſs.

m, Part of the maſtoid groove.

n, The ſtyloid proceſs.

o, The foramen maſtoideum.

p, The baſe, or upper part of the maſtoid proceſs.

q, The inferior and anterior part of the bone, which joins the os ſphenoides.

r, A ſmall portion of the Euſtachian tube.

s, The point of the pars petroſa.

FIG. 8.

The Inner Surface of the TEMPORAL BONE.

a, The upper edge of the ſquamous proceſs.

b, The middle of that proceſs, marked by the convolutions of the brain.

c, A part of the bone which joins the os ſphenoides.

d, Nitch which receives the under and back part of the parietal bone.

e, The upper part of the pars petroſa.

f, A groove which lodges the ſuperior petroſal ſinus.

g, Foſſa which lodges part of the lateral ſinus.

h, Meatus auditorius internus.

i, Nitch which aſſiſts in forming the foramen lacerum.

k, Part of the foſſa which lodges the beginning of the internal jugular vein.

l, The poſterior part of the bone which joins the os occipitis.

m, The foramen maſtoideum.

n, A portion of the maſtoid proceſs.

o, The maſtoid groove.

p, The ſtyloid proceſs.

q, The inner extremity of the pars petroſa divided into two portions.

FIG. 9.

The Upper and Inner Surface of the ŒTHMOID BONE.

a, The anterior extremity of the bone, terminating in a ſmall flat proceſs.

b, The criſta galli.

c, *c*, The cribriform plate, for the paſſage of the olfactory nerves.

d, *d*, The poſterior œthmoid cells.

e, The back-part of the naſal plate, which forms part of the ſeptum narium.

f, *f*, The poſterior margin of the bone.

g, The os planum of the left ſide.

h, *h*, The ſphenoid cornua, or triangular bones, which join the body of the ſphenoid bone; their fore-parts being fixed to the œthmoid one.

FIG. 10.

The Under and Outer Surface of the ŒTHMOID BONE.

a, The naſal plate, which forms the upper part of the ſeptum narium.

b, *b*, The

b, b, The offa ſpongioſa ſuperiora, convex towards the ſeptum of the noſe, and concave outwards.

Between the offa ſpongioſa and naſal plate deep chinks are ſeen, which ſeparate theſe proceſſes from each other.

c, c, Inequalities by which this bone is joined to the frontal one.

d, d, The ſphenoid cornua.

FIG. 11.

The Inner or Upper Surface of the SPHENOID BONE.

a, The fore-part of the bone, which joins the under and back part of the frontal one.

b, b, The temporal plates or proceſſes.

c, c, The tranſverſe proceſſes.

d, A ſmall anterior proceſs, which unites with the œthmoid bone.

e, The proceſſus olivaris.

f, f, The foramina optica.

g, g, The anterior clinoid proceſſes.

h, h, The poſterior clinoid proceſſes.

i, i, Part of the foramina lacera.

k, k, Impreſſions made by the internal carotid arteries.

l, The ſella Turcica.

m, m, The temporal foſſæ, which receive the lateral lobes of the brain.

n, n, The foramina rotunda.

o, o, The foramina ovalia.

p, p, The foramina ſpinalia.

q, q, Ragged edge of the bone which aſſiſts in forming the ſphenoid ſuture.

r, The back-part of the body of the bone, which joins the cuneiform proceſs of the occipital one.

s, s, Part of the ſpinous, and,

t, t, Part of the pterygoid proceſſes.

FIG.

FIG. 12.

The Outer or Under Surface of the SPHENOID BONE.

a, The proceſſus azygos.

b, *b*, The ſphenoid cornua.

c, *c*, The openings of the ſphenoid ſinuſes.

d, *d*, The foramina lacera.

e, The fore-part of the body of the bone.

f, *f*, The outer ſurface of the tranſverſe proceſſes.

g, *g*, The orbitar plates.

h, *h*, The temporal proceſſes.

i, *i*, The aſperities, by which this bone is joined to the oſſa malarum.

k, *k*, Gutters, which lodge branches of the fifth pair of nerves.

l, *l*, The foramina rotunda.

m, *m*, The foramina pterygoidea.

n, *n*, Anterior openings, which aſſiſt in forming the ſphenoid fiſſures.

o, *o*, The foramina ovalia.

p, *p*, The ſpinous proceſſes.

q, *q*, The roots of the pterygoid proceſſes.

r, *r*, The internal plates of the pterygoid proceſſes.

s, *s*, Hook-like proceſſes at the extremities of the internal plates.

t, *t*, The external plates of the pterygoid proceſſes.

u, *u*, Parts of the bone adapted to the oſſa palati.

v, *v*, Poſterior openings, common to the occipital and temporal bones, over which the internal carotid arteries paſs.

Tab. IV.

Fig. 1.

Fig. 2.

Fig. 3.

Fig. 4.

Fig. 5.

Fig. 6.

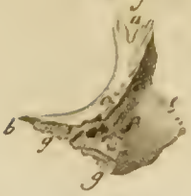

Fig. 7.

Fig. 8.

Fig. 9.

Fig. 10.

Fig. 11.

Fig. 12.

Fig. 13.

Fig. 14.

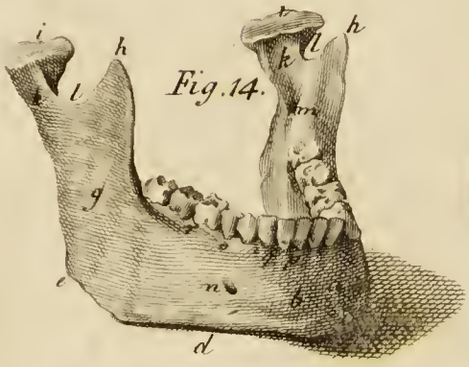

Fig. 15.

Fig. 16.

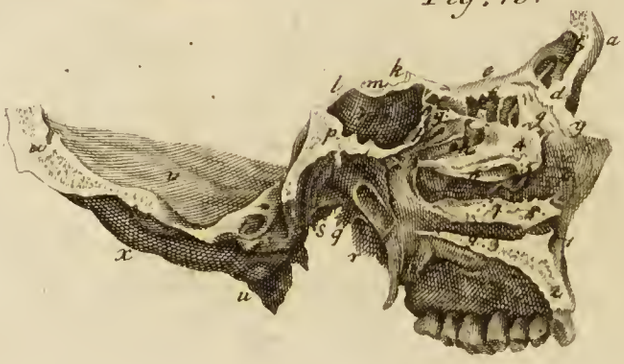

Fig. 17.

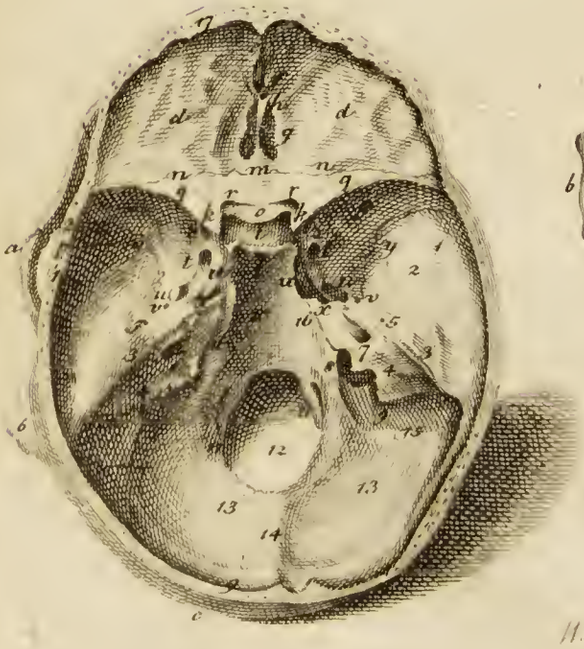

Fig. 19.

Fig. 18.

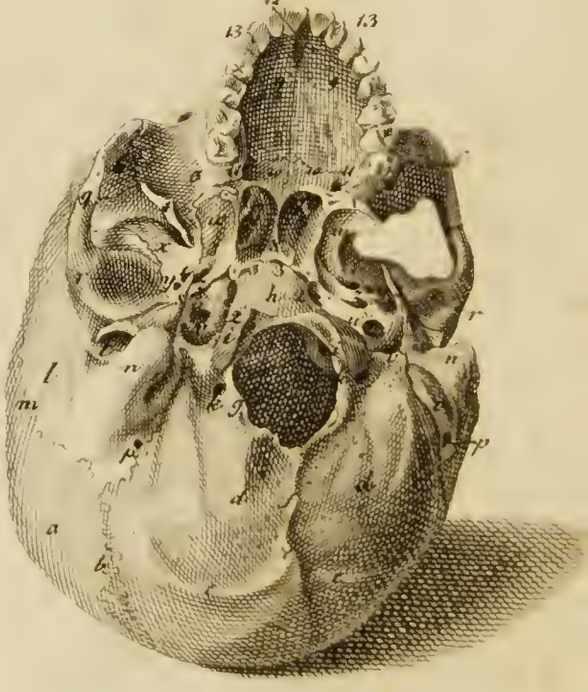

W. Archibald Sc.

TABLE IV.

REPRESENTS the different BONES of the FACE, a Section of the NOSE, the Inner, and Under Sides of the SKULL, with the Small Bone termed Os HYOIDES.

FIG. 1.

The Outer Surface of the OSSA NASI.

a, a, The upper part, which is joined to the frontal bone.

b, b, The lower ragged end, to which the cartilage of the nose is fixed.

The black points represent holes penetrating the bones.

FIG. 2.

The Inner Surface of the OSSA NASI.

a, a, The inner edge of each, thick and strong, where it joins its fellow, and sends a spine backwards, to be fixed to the partition of the nose.

b, b, The cavity which forms part of the arch of the nose.

FIG. 3.

The Outer Surface of the Left OS UNGUIS.

a, The lacrymal process, perforated by numerous holes.

b, The orbitar process.

c, The ridge which separates the processes.

FIG. 4.

The Inner Side of the OS UNGUIS, with Eminences and Cavities which belong to the Œthmoid Cells.

FIG. 5.

The Outer Surface of the Right OS MALÆ.

a, The ſuperior orbitar proceſs.

b, The inferior orbitar proceſs.

c, The internal orbitar plate.

d, The maxillary proceſs.

e, The zygomatic proceſs.

f, The external orbitar hole.

g, *g*, The under and outer edge of the orbit.

h, Part of the inner rough ſurface of the maxillary proceſs.

i, The zygomatic nitch.

FIG. 6.

The Inner Surface of the ſame OS MALÆ.

a, *b*, *c*, *d*, *e*, as in Fig. 5.

f, The internal foſſa, and ſituation of the external orbitar hole

g, *g*, Rough edge which joins the os malæ to the ſuperior maxillary bone at the external orbitar ſuture.

FIG. 7.

The Outer Side of the Right Superior MAXILLARY BONE, *with a ſmall Portion of the* OS PALATI.

a, The maxillary foſſa.

b, The naſal proceſs of the maxillary bone.

c, Inequalities, by which it is joined to the os frontis.

d, The angle which is joined to the under end of the os naſi, and to the cartilage of the noſe.

e, The orbitar plate.

f, The edge of the orbit.

g, A groove which belongs to the infra-orbitar canal.

h, *h*, *i*, *i*, The malar proceſs.

k, *k*, The alveolar proceſs.

l, The maxillary tuberoſity.

m, A ſmall portion of the os palati.

n, *n*, Small holes which penetrate the bone.

o, The fore-part of the noſtril.

p, The naſal ſpine, forming part of the partition of the noſe.

q, The palate plate.

r, The foramen infra-orbitarium.

s, *s*, The two dentes inciſores.

t, The dens caninus.

u, *u*, The five dentes molares.

FIG. 8.

The Inner Surface of the SUPERIOR MAXILLARY, *and of the* PALATE BONES.

a, The naſal proceſs, or upper angle.

b, The middle angle at the baſe of the naſal proceſs.

c, Inequalities, where the fore-part of the os ſpongioſum inferius is fixed.

d, The palate proceſs.

e, The alveolar proceſs.

f, The irregular ſurface of the palate proceſs, which joins its fellow of the oppoſite ſide.

g, The maxillary ſinus.

h, Small cells in the upper part of the bone.

i, The lacrymal foſſa.

k, The palate fiſſure, which aſſiſts in forming the foramen inciſivum.

 l, The

l, The ſuture which unites this bone to the os palati.

m, The part of the bone which forms the largeſt ſhare of the naſal foſſa.

n, The naſal ſpine.

o, Rough ſurface, where the fore-part of the bone joins its fellow.

p, The palate bone.

q, The ſmall ſinus commonly found in this bone.

r, The naſal lamella of the palate bone, forming part of the maxillary ſinus, and of the cavity of the noſtril.

s, An eminence, where this bone is connected to the inferior ſpongy one.

t, The rough ſurface, where the two palate bones unite.

u, The hole proper to this bone.

v, The foramen guſtativum, or palatinum poſterius.

w, The pterygoid proceſs.

x, *x*, The teeth.

FIG. 9.

The Poſterior, and almoſt the whole of the External Surface of the Left OS PALATI.

a, The palate plate.

b, The pterygoid proceſs.

c, The naſal plate.

d, The orbitar proceſs.

e, A ſmall ſinus, correſponding with thoſe of the œthmoid bone.

f, The notch which forms part of the foramen ſpheno-palatinum.

g, A ſmall hole which penetrates the bone.

h, Part

h, Part of the groove which helps to form the foramen guſtativum.

FIG. 10.

The Anterior, and almoſt all the External Surface of the ſame PALATE BONE.

a, A notch which aſſiſts in forming the foramen guſtativum.
b, The orbitar proceſs.
c, The palate plate.
d, The naſal plate.
e, The groove which helps to form the foramen guſtativum.
f, The pterygoid proceſs.

FIG. 11.

The External Concave Surface of the OS SPONGIOSUM INFERIUS *of the Left Side.*

a, The under edge of the bone turning outwards.
b, The upper edge, ſending down a hook-like plate, to cover a portion of the maxillary ſinus.
c, The broad anterior extremity, where the connection is chiefly made with the ſuperior maxillary bone.
d, The poſterior extremity, narrow, and irregular in its ſurface.
e, The external ſurface, with numerous ſmall holes, which mark its poroſity.
f, The part which joins the os unguis, to form a ſhare of the lacrymal groove.

FIG. 12.

The Inner Convex Surface of the ſame OS SPONGIOSUM INFERIUS, *which, like the External Surface, is alſo of a ſpongy texture.*

FIG.

FIG. 13.

The Left Side of the VOMER.

a, The hollow ſurface, which receives the proceſſus azygos of the ſphenoid bone.

b, The anterior and upper edge, which is connected to the naſal plate of the œthmoid bone, and middle cartilage of the noſe.

c, The inferior edge, which is connected to the palate plates of the ſuperior maxillary and palate bones.

d, A ridge upon the ſide of the vomer.

FIG. 14.

The LOWER JAW, viewed from the Right Side.

a, The ſymphyſis of the jaw.

b, *b*, Muſcular prints.

c, Another depreſſion, which marks the middle of the chin.

d, The baſe of the jaw.

e, The angle of the right ſide.

f, The inner ſurface of the angle of the left ſide.

g, The aſcending plate, with muſcular prints.

h, *h*, The coronoid, and,

i, *i*, The condyloid proceſſes.

k, *k*, The cervix on each ſide.

l, *l*, Semilunar notches between the proceſſes.

m, The poſterior maxillary foramen.

n, The anterior maxillary foramen.

o, The alveoli of the teeth.

p, The two dentes inciſores of the right ſide.

q, The dens caninus.

r, The five dentes molares.

FIG.

FIG. 15.

The TEETH.

a, 1. The base or body of the tooth, covered with enamel.
2. The root, or fang, destitute of enamel.
3. The neck, or collar.

b, Sections of two teeth, to shew the extent of the enamel, with the direction of its fibres—The fibrous and lamellated structure of the osseous part—The internal cavity for containing the pulp.

a, A fore and back view of the incisores of the under jaw.

b, The similar teeth of the upper jaw.

c, A fore and back view of the dentes canini.

d, The two small molares.

e, The three large molares.

FIG. 16.

The Left Portion of the Base of the SKULL, divided from the Septum Narium, by a perpendicular Section, proceeding in a straight line from before backwards.

a, Part of the frontal bone.

b, The posterior lamina, called vitrea.

c, The frontal sinus.

d, Part of the transverse suture, dividing the frontal from the superior maxillary bone.

e, Part of the frontal bone, contiguous to the os œthmoides.

f, The upper part of the œthmoid bone.

g, *g*, The cells of the œthmoid bone, the anterior of which are entire, the rest laid open.

h, *h*, Openings of the œthmoid cells into the nose.

i, The uppermost passage of the nostril.

k, The

k, The left anterior clinoid proceſs of the ſphenoid bone.

l, The poſterior clinoid proceſs.

m, The ſella Turcica.

n, The left ſphenoid ſinus.

o, The part where the ſinus opens into the upper and back part of the noſe.

p, A ſection of the body of the ſphenoid, and of the cuneiform proceſs of the occipital bone.

q, Spinous proceſs of the ſphenoid bone.

r, The internal pterygoid plate.

s, The fore-part of the meatus auditorius.

t, The ſuperior condyloid foramen.

u, The maſtoid proceſs of the temporal bone.

v, The inner ſide of the occipital bone.

w, The cut edge of that bone.

x, The under and outer part of that bone.

y, The naſal proceſs of the ſuperior maxillary bone.

z, The inner ſide of that bone, forming the middle paſſage of the noſtril.

1, Part of the ſame bone, which forms the beginning of the lower paſſage of the noſtril.

2, A ſection of the alveolar proceſs.

3, A ſection of the oſſeous palate.

4, The os ſpongioſum ſuperius.

5, The middle paſſage of the noſtril.

6, The opening of the antrum maxillare.

7, The os ſpongioſum inferius.

8, That part of the inferior ſpongy bone which lies over the opening of the lacrymal duct.

9, The loweſt paſſage of the noſtril.

FIG.

TABLE IV. CONTINUED.

FIG. 17.

A View of the Inner Surface of the Base of the CRANIUM.

a, The zygoma.

b, The maſtoid proceſs of the temporal bone.

c, The external ſurface of the occipital bone.

d, *d*, The frontal foſſæ marked by the brain.

e, Part of the frontal ſpine.

f, The foramen cæcum, placed at the bottom of the frontal ſpine.

g, The cribriform plate of the œthmoid bone.

h, The criſta Galli of this bone.

i, The ſella Turcica of the ſphenoid bone.

k, *k*, The anterior clinoid proceſſes.

l, The poſterior clinoid proceſs.

m, Small proceſs of the ſphenoid bone, fixed to the œthmoid one.

n, *n*, Part of the ſphenoid ſuture.

o, The proceſſus ſemi-olivaris.

p, *p*, The temporal foſſæ.

q, *q*, The tranſverſe ſpinous proceſſes.

r, *r*, The foramina optica.

s, *s*, A ſmall portion of the foramina lacera.

t, *t*, The foramina rotunda.

u, *u*, The foramina ovalia.

v, *v*, The foramina ſpinalia.

w, *w*, Impreſſions made by the internal carotid arteries.

x, *x*, Points of the partes petroſæ of the temporal bones, and, before theſe, irregular openings, which in the ſubject are filled, partly by bone, and partly by a ligamentous ſubſtance.

y, *y*, Suture

y, *y*, Suture common to the ſphenoid and temporal bones.

1, 1, Squamous parts of the temporal bones, which complete,

2, 2, The temporal foſſæ for the lateral lobes of the brain.

3, 3, Ridge of the pars petroſa on each ſide, to which the tentorium is fixed.

4, 4, Poſterior ſurface of the pars petroſa on each ſide, which is oppoſed to the cerebellum.

5, The foramen innominatum.

6, The groove which lodges the ſuperior petroſal ſinus.

7, 7, The meatus auditorii interni.

8, 8, The foramina lacera common to the temporal and occipital bones.

9, 9, The foſſæ for lodging the lateral ſinuſes.

10, The cuneiform proceſs of the occipital bone.

11, 11, The anterior condyloid foramina of that bone.

12, The foramen magnum.

13, 13, The inferior occipital foſſæ, which lodge the correſponding lobes of the cerebellum.

14, The inferior limb of the cruciform ſpine, to which the falx minor is fixed.

15, Part of the lambdoid ſuture.

16, 16, The foſſæ for the inferior petroſal ſinuſes.

17, 17, The cut edge of the ſkull.

FIG. 18.

Repreſents the Outer and Under Surface of the SKULL, *turned a little to the Left Side.*

a, The parietal bone.

b, The lambdoid ſuture.

c, *c*, The large tranſverſe arched ridge of the occipital bone.

d, *d*, The

d, d, The ſmaller tranſverſe ridge, with muſcular prints on each ſide of it.

e, Spinous tuberoſity, ſeen in ſome ſkulls only.

f, The perpendicular ſpine.

g, The foramen magnum.

h, The cuneiform proceſs.

i, i, The articular or condyloid proceſſes.

k, k, The poſterior condyloid foramina.

l, The ſquamous portion of the temporal bone.

m, The ſquamous ſuture.

n, n, The maſtoid proceſſes.

o, o, The maſtoid fiſſures.

p, The foramen maſtoideum.

q, The zygoma and zygomatic ſuture.

r, The glenoid cavity at the root of the zygoma, for the articulation of the lower jaw.

s, s, The ſtyloid proceſſes, behind the roots of which the foramina ſtylo-maſtoidea are concealed.

t, The meatus auditorius externus.

u, u, The foramina carotica.

v, v, The jugular foſſæ.

w, w, The pterygoid foſſæ, at the ſides of which are the pterygoid plates.

x, The temporal proceſs of the ſphenoid bone.

y, The ſpinous proceſs and ſpinous hole of that bone.

z, z, The oſſeous mouths of the Euſtachian tubes.

1, 1, The foramina ovalia.

2, 2, Paſſages common to the occipital, temporal, and ſphenoid bones.

3, 3, Foramina pterygoidea.

4, The inferior orbitar fiſſure.

5, The

5, The under part of the tuber or bulge of the ſuperior maxillary bone.

6, 6, The inner ſides of the oſſa malarum.

7, 7, The ſuperior and inferior ſpongy bones, with a view of the back-part of the noſtrils.

8, The poſterior edge of the vomer.

9, 9, The palate plates of the ſuperior maxillary bones, with the longitudinal palate ſuture.

10, 10, The palate plates of the palate bones, with the tranſverſe, and continuation of the longitudinal palate ſutures.

11, 11, The foramina guſtativa, or poſterior palate holes.

12, The foramen inciſivum, or anterior palate hole.

13, 13, The teeth, divided into two inciſores, one caninus, two ſmall molares, and three large molares on each ſide.

FIG. 19.

The OS HYOIDES, *ſeen from the Upper and Fore Part.*

a, The body of the os hyoides.

b, *b*, Its cornua.

c, *c*, Its appendices.

Tab. V

Occipito - Frontalis Fig. 1 arises from the transverse ridge of Occipital bone as far as the Mastoid process, the fibres ascend and form a broad thin tendon is inserted on each side, into the skin of the forehead and eyebrows, intermixing with the fibres of the orbicularis palpebarum and corrugator supercilii, sending down a slip on each side of the nose called often the pyramidalis nasi - Use to pull the skin of the head backwards raise the eyebrows, and corrugate the skin of the forehead -

Muscles moving the External ear -

Attollens Aurem arises from the tendon of the occipito frontalis, and from the aponeurosis of the temporal muscle - Inserted into the upper part of the cartilage of ~~the ear of~~ of the ear opposite the antihelix -

Use To draw the ear upwards -

Anterior Auris arises thin and membranous, from

[illegible] commence on the [illegible]
[illegible] the [illegible]

TAB. V.

Fig. 1.

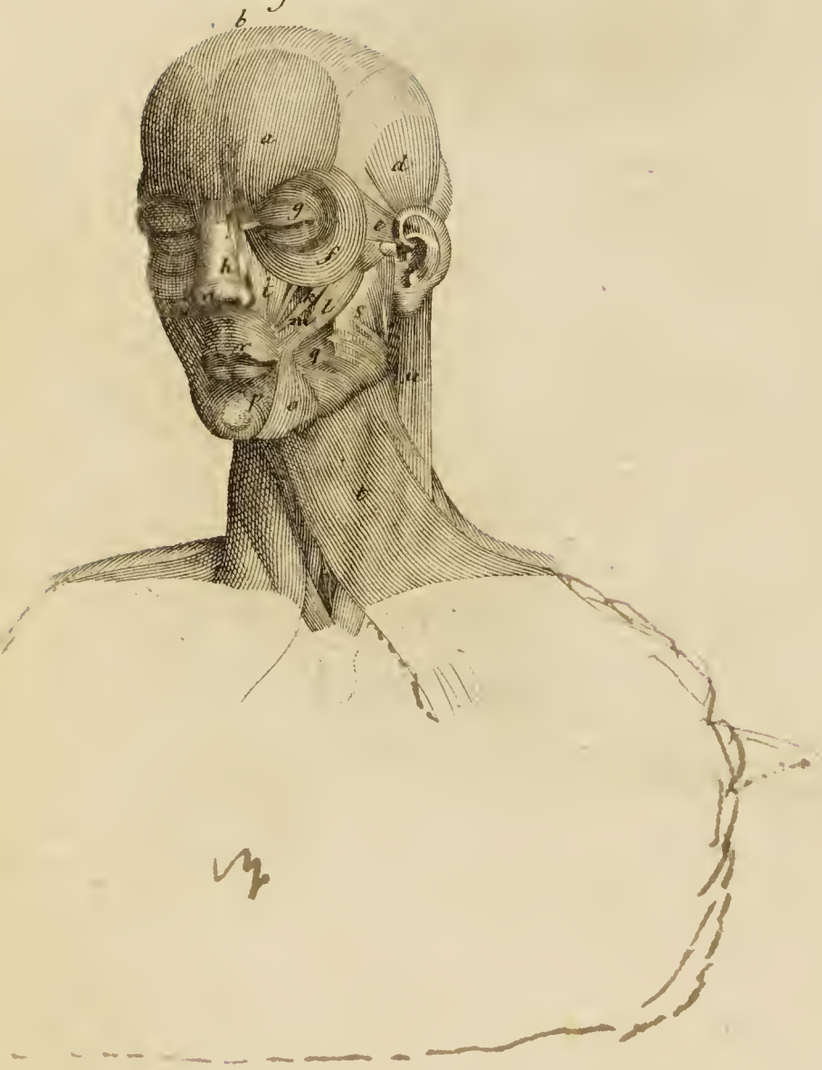

Fig. 2.

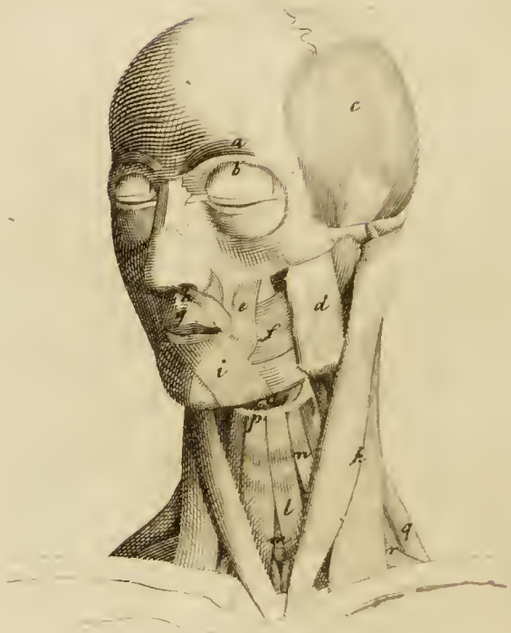

Fig. 3.

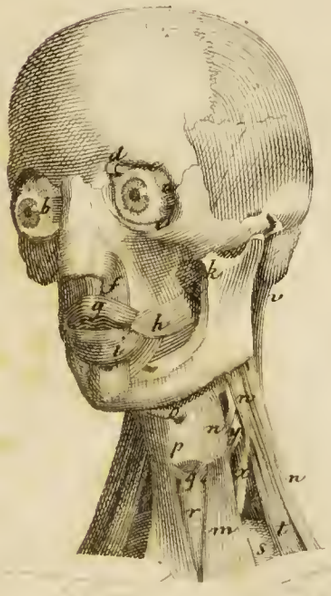

Fig. 4.

pointes into a small eminence on the back of the
helix, opposite to the concha. Use to draw the ears
ence a little forwards and upwards.

TABLE V.

REPRESENTS the MUSCLES situated on the Fore-part of the HEAD and NECK.

FIG. 1.

The First Order of MUSCLES on the Fore-part of the HEAD and NECK, after the Integuments have been removed.

a, The frontal part of the occipito-frontalis.
b, The tendon of that muſcle.
c, A fleſhy ſlip deſcending from the occipito-frontalis over the root of the noſe.
d, The attollens aurem.
e, The anterior auris.
f, The orbicularis palpebrarum.
g, The ciliary part of the orbicularis.
h, The compreſſor naris.
i, The levator labii ſuperioris alæque naſi.
k, The zygomaticus minor.
l, The zygomaticus major.
m, The levator anguli oris.
n, The cartilage of the noſe.
o, The depreſſor anguli oris.
p, The depreſſor labii inferioris.
q, The buccinator.
r, The orbicularis oris.
s, The maſſeter.
t, The platyſma myoides, its upper end paſſing over the jaw.
u, The ſterno-cleido-maſtoideus.

FIG.

FIG. 2.

The Second Order of MUSCLES *on the Fore-part of the* HEAD *and* NECK.

a, The corrugator ſupercilii.

b, The levator palpebræ ſuperioris.

c, The temporalis, the tendon of which is ſeen paſſing under the zygoma.

d, The maſſeter.

e, The levator anguli oris.

f, The buccinator.

g, The orbicularis oris.

h, The naſalis labii ſuperioris, at the upper ſide of which is a portion of the depreſſor labii ſuperioris alæque naſi.

i, The depreſſor labii inferioris.

k, The ſterno-cleido-maſtoideus.

l, The ſterno-hyoideus.

m, Part of the trachea.

n, The omo-hyoideus.

o, The hyo-thyroideus.

p, The os hyoides.

q, The levator ſcapulæ.

r, The ſcalenus medius.

FIG. 3.

The Third Order of MUSCLES *on the Fore-part of the* HEAD *and* NECK.

a, The inſertion of the abductor oculi.

b, The adductor oculi of the right ſide.

c, The inſertion of the levator oculi.

d, The

d, The trochlea, and part of the tendon of the obliquus ſuperior.

e, The obliquus inferior.

f, The depreſſor labii ſuperioris et alæ naſi.

g, The orbicularis oris.

h, The buccinator.

i, The levator labii inferioris.

k, Part of the pterygoideus externus.

l, Part of the pterygoideus internus.

m, The ſterno-thyroideus.

n, The thyro-hyoides.

o, The os hyoides.

p, The thyroid cartilage.

q, The cricoid cartilage, with the two crico-thyroid muſcles ariſing from it.

r, The trachea.

s, Part of the pleura.

t, The ſcalenus anticus.

u, The ſcalenus medius.

v, A portion of the trachelo-maſtoideus.

w, The rectus capitis anterior major.

x, The longus colli.

y, The conſtrictor pharyngis inferior.

FIG. 4.

The Fourth Order of MUSCLES *on the Fore-part of the* HEAD *and* NECK.

a, The levator palpebræ ſuperioris.

b, The levator oculi.

c, The adductor oculi.

d, The

d, The abductor oculi.

e, The depressor oculi.

f, The obliquus superior.

g, The obliquus inferior.

h, The pterygoideus internus.

i, The obliquus superior capitis.

k, The scalenus medius.

l, The longus colli.

m, *m*, The intertransversales colli.

Tab. VI.

Fig. 1.

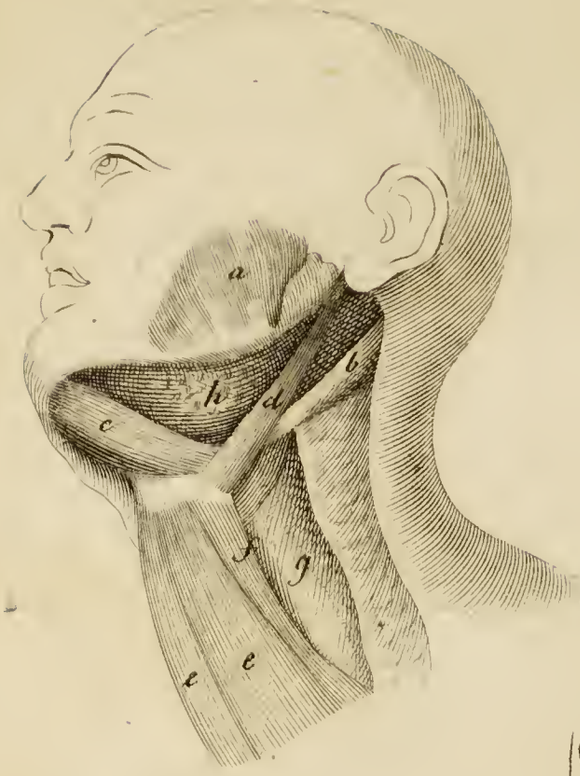

Fig. 2.

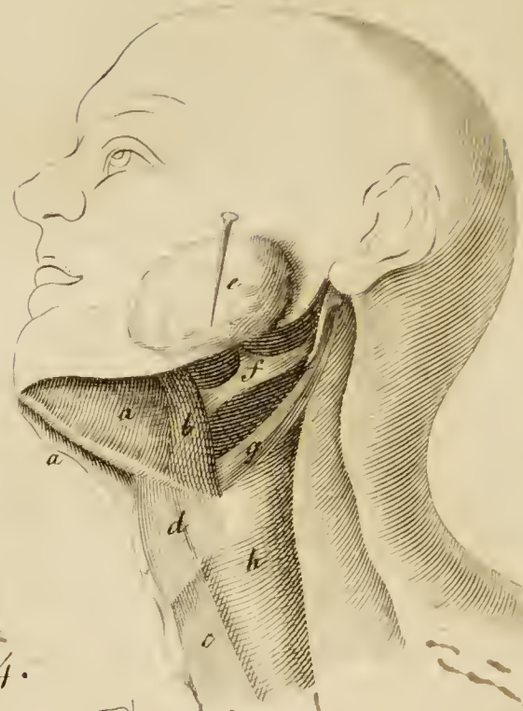

Fig. 4.

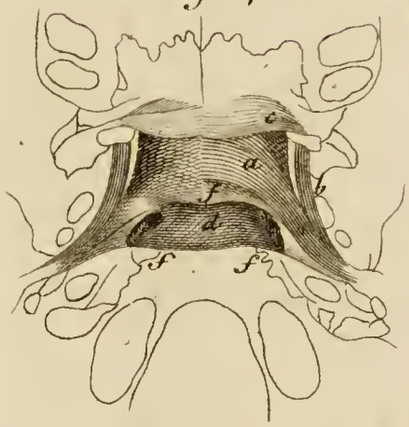

Fig. 3.

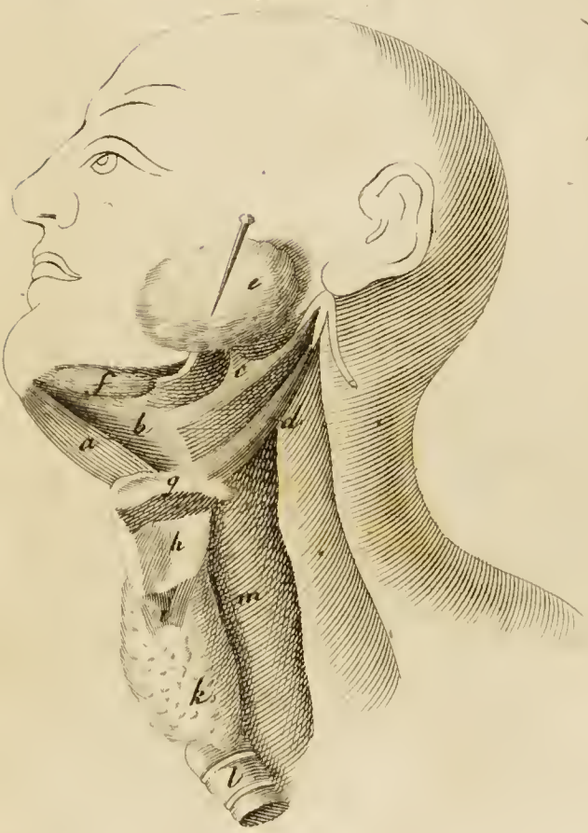

Fig. 5.

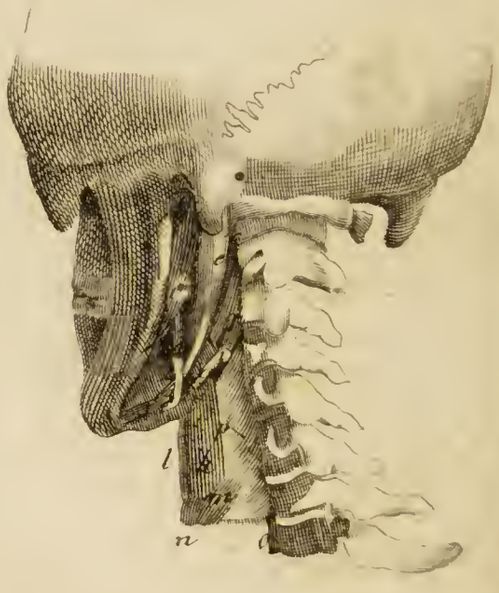

Fig. 6.

Fig. 7.

TABLE VI.

REPRESENTS the MUSCLES ſituated about the THROAT.

FIG. 1.

Part of the Muſcles of the OS HYOIDES.

a, Part of the maſſeter.
b, The poſterior head of the digaſtric.
c, Its anterior head.
d, The ſtylo-hyoideus, with the tendon of the digaſtric paſſing through it.
e, *e*, The ſterno-hyoidei.
f, The omo-hyoideus.
g, The pharynx.
h, The ſubmaxillary gland.

FIG. 2.

MUSCLES deeper ſeated than the former.

a, *a*, The mylo-hyoidei.
b, The hyo-gloſſus.
c, The ſterno-thyroideus.
d, The thyro-hyoideus.
e, The ſubmaxillary gland, raiſed from its place behind the angle of the lower jaw.
f, The ſtylo-gloſſus, ſupported by a ligament.
g, The ſtylo-pharyngeus.
h, The pharynx.

FIG. 3.

MUSCLES deeper ſeated than the former.

a, The genio-hyoideus.

b, The genio-hyo-gloſſus.

c, The ſtylo-gloſſus, with its ſupporting ligament.

d, The ſtylo-pharyngeus.

e, The ſubmaxillary gland, raiſed, by which its duct is ſeen advancing towards its termination at the ſide of the fræ-num linguæ.

f, The ſublingual gland.

g, The os hyoides.

h, The thyroid cartilage.

i, The cricoid cartilage, with the crico-thyroid muſcles.

k, The thyroid gland.

l, The trachea.

m, The pharynx.

FIG. 4.

Muſcles of the PALATE, viewed on the Under Side.

a, The levator palati.

b, *c*, The circumflexus palati; *c*, Its tendon paſſing over the hook-like proceſs of the pterygoid plate.

d, The membrane of the palate.

e, *e*, The mouths of the Euſtachian tubes.

f, *f*, *f*, The circumference from which the membrane of the palate is cut off.

FIG. 5.

A Lateral View of the MUSCLES, ſeated under the HEAD, and before the Vertebræ of the NECK.

a, The pterygoideus externus.

b, The

b, The pterygoideus internus.
c, The mylo-hoideus.
d, The ſtylo-hyoideus.
e, *f*, The digaſtricus.
g, *h*, The hyo-gloſſus.
i, The os hyoides.
k, The thyro-hyoideus.
l, The thyroid cartilage.
m, The crico-thyroideus.
n, The cricoid cartilage.
o, A ſection of the œſophagus.
p, The conſtrictor pharyngis inferior.
q, The conſtrictor pharyngis medius.
r, The conſtrictor pharyngis ſuperior.

FIG. 6.

A Back-View of the PHARYNX, *with the Under Part of the* BONES *of the* HEAD, *to which the Pharynx is fixed.*

a, The upper point of the conſtrictor pharyngis inferior.
b, The under end of the pharynx, and inner tranſverſe fibres of the œſophagus.
c, *c*, The outer fibres of the œſophagus, deſcending obliquely backwards on each ſide.
d, A ſection of the œſophagus.
e, *e*, A ſection of the trachea.
f, The extremities of the cornua of the os hyoides, with the ligaments which join them to the ſuperior cornua of the thyroid cartilage.
g, *g*, The conſtrictor pharyngis medius, on each ſide.
h, *h*, The conſtrictor pharyngis ſuperior, on each ſide.

 i, The

i, The naked membrane of the pharynx.

k, *k*, The ſtylo-pharyngeus, on each ſide.

l, *l*, The ſtyloid proceſſes of the temporal bones.

m, *m*, The pterygoid proceſſes of the ſphenoid bone.

n, *n*, The backmoſt tooth of the upper and under jaws, on each ſide.

FIG. 7.

The MUSCLES *lying immediately under the* MEMBRANE *of the* PHARYNX, *which, with the* ŒSOPHAGUS *and* TRACHEA, *are removed.*

a, The levator palati.

b, The azygos uvulæ.

c, The palato-pharyngeus.

d, The part of it which paſſes under the levator palati.

e, That part of it, called by ALBINUS *Salpingo Pharyngeus.*

f, Part of the common end of the palato-pharyngeus and ſtylo-pharyngeus.

g, The poſterior edge of the velum palati.

h, The uvula.

i, The tonſil, projecting before the palato-pharyngeus muſcle.

k, The tongue.

l, The epiglottis.

m, *m*, The points of the arytenoid cartilages.

n, The arytenoideus obliquus.

o, *o*, The arytenoideus tranſverſus.

p, The crico-arytenoideus poſticus.

q, The cricoid cartilage.

r, The poſterior edge of the thyroid cartilage, which conceals the two ſmall muſcles termed *Crico-arytenoideus Lateralis* and *Thyro-arytenoideus.*

TAB. VII.

Fig. 1.

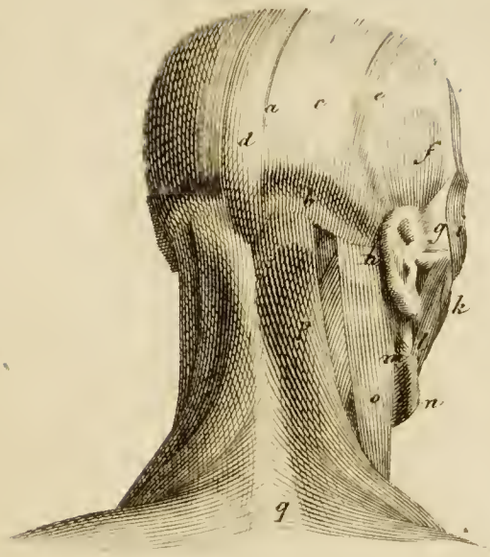

Fig. 2.

Fig. 3.

Fig. 4.

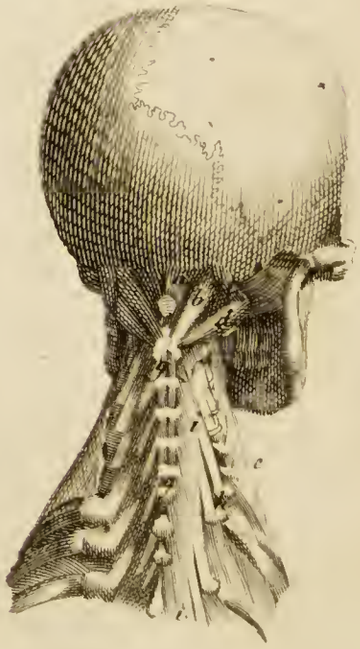

TABLE VII.

REPRESENTS the MUSCLES ſituated on the BACK-PART of the HEAD and NECK.

FIG. 1.

The Firſt Order of MUSCLES on the Back-part of the HEAD and NECK, after the Integuments have been removed.

a, The occipital part of the occipito-frontalis muſcle.
b, The fleſhy, and,
c, The tendinous part of this muſcle.
d, A tendinous membrane, joining the oppoſite ſides of the muſcle.
e, Part of the tendinous membrane, covering the upper part of the temporal muſcle.
f, The attollens aurem.
g, The anterior auris.
h, A ſmall portion of the retrahentes auris.
i, The back-part of the orbicularis palpebrarum.
k, The zygomaticus major.
l, The maſſeter.
m, The pterygoideus internus.
n, The platyſma myoides.
o, The ſterno-cleido-maſtoideus.
p, The upper end of the trapezius.
q, The tendinous portion of that muſcle, in the nape of the neck, called *Ligamentum Nuchæ*.

FIG.

FIG. 2.

The Second Order of MUSCLES *on the Back-part of the* HEAD *and* NECK.

a, The temporalis, its aponeurosis being removed.

b, The tendon of the temporal muscle, passing under the zygoma.

c, The pterygoideus internus.

d, The masseter.

e, The mylo-hyoideus.

f, The levator scapulæ.

g, The splenius.

h, The upper end of the complexus.

i, A portion of the rhomboides major.

k, Part of the rhomboides minor.

l, The upper end of the serratus posticus superior.

FIG. 3.

The Third Order of MUSCLES *on the Back-part of the* HEAD *and* NECK.

a, The back-part of the buccinator.

b, The pterygoideus internus.

c, The mylo-hyoideus.

d, *e*, *f*, The complexus; *f*, A fleshy slip from the spinous process of the first dorsal vertebra.

g, The trachelo-mastoideus.

h, The scalenus medius.

i, The scalenus posticus.

k, The semi-spinalis colli.

l, Interspinales colli.

m, Obliquus

m, Obliquus capitis ſuperior.

n, Tranſverſalis colli.

o, The upper end of the longiſſimus dorſi, joining the trachelo-maſtoideus and cervicalis deſcendens.

p, The fleſhy ſlip from the ſacro-lumbalis, called *Cervicalis Deſcendens*.

FIG. 4.

The Fourth Order of MUSCLES *on the Back-part of the* HEAD *and* NECK.

a, The rectus capitis poſterior minor.

b, The rectus capitis poſterior major.

c, The obliquus capitis ſuperior.

d, The obliquus capitis inferior.

e, The ſcalenus medius.

f, The upper end of the multifidus ſpinæ.

g, *g*, The interſpinales colli.

h, *h*, The intertranſverſales colli.

i, *i*, The ſemiſpinalis colli.

TAB. VIII.

TABLE VIII.

REPRESENTS MUSCLES on the Fore-part of the TRUNK of the BODY.—On the Right Side, the MUSCLES are expoſed which lie immediately under the Common Integuments.—On the Left Side, the MUSCLES are ſeen which are placed under the former.

THORAX.

a, The under end of the platyſma myoides.

b, The pectoralis major, with the deltoides at the outer ſide of it.

c, *c*, Part of the ſerratus magnus.

d, The edge of the latiſſimus dorſi.

e, The ſubclavius.

f, The pectoralis minor.

g, *g*, The ſerratus magnus. Farther out, the ſubſcapularis is ſeen.

h, *h*, The intercoſtales interni, the tendinous faſcia being removed.

ABDOMEN.

i, *i*, The obliquus deſcendens externus.

k, The beginning of the tendon of that muſcle.

l, The obliquus internus, ſhining through the tendon of the obliquus externus.

m, *m*, The linea ſemilunaris.

n, *n*, The rectus abdominis, alſo ſhining through the tendon of the obliquus externus.

o, *o*, The

o, *o*, The tendinous interſections of the rectus.

p, *p*, The linea alba.

q, The umbilicus.

r, The pyramidales.

s, The ring of the external oblique muſcle, tranſmitting the ſpermatic cord.

t, The cremaſter muſcle, covering the ſpermatic cord.

u, The lower edge of the external oblique muſcle, termed *Ligament of* POUPART.

v, The obliquus internus aſcendens.

w, *w*, The tendon of the obliquus internus, part of which is left covering the outer edge of the rectus muſcle. Between *v* and *w* the tendon ſplits into two layers, which incloſe the rectus. From *w* to the pubis the whole of the tendon goes before the rectus.

x, *x*, The rectus abdominis.

y, *y*, *y*, The tendinous interſections of the rectus.

z, The cremaſter teſtis.

Tab. IX.

Fig. 1.

Fig. 2.

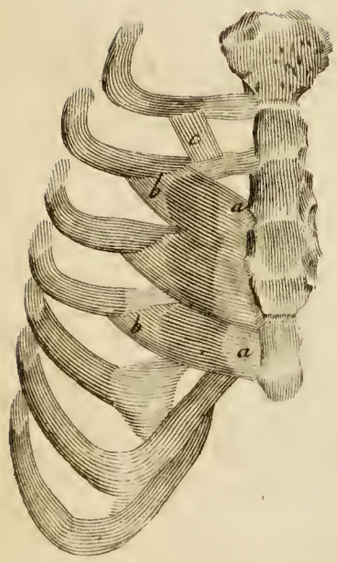

Fig. 3.

TABLE IX.

REPRESENTS the Third Layer of MUSCLES on the Right, and the Fourth Layer of MUSCLES on the Left Side of the Anterior Part of the TRUNK of the BODY.

FIG. 1.

THORAX.

a, The intercoſtales externi.

b, *b*, *b*, *b*, The intercoſtales interni.

c, *c*, The convex or thoracic ſide of the diaphragm.

d, Its middle tendon.

e, *f*, *g*, *h*, The fleſhy origins of the diaphragm, ſeparated from the inferior margin of the thorax.

ABDOMEN.

i, The tranſverſalis abdominis.

k, That portion of the tendons of the internal oblique and tranſverſe muſcles, which lie behind the rectus.

l, The remains of the tendons of the oblique and tranſverſe muſcles, forming the linea alba.

m, The ſpermatic veſſels, paſſing under the edge of the tranſverſe muſcle.

n, The peritoneum, marked by one of the umbilical arteries and the urachus.

o, The tendinous crura of the inferior muſcle of the diaphragm.

p, The paſſage for the aorta, between the crura.

q, *q*, The fleſhy heads of the ſmall muſcle of the diaphragm.

r, The part where the fibres of the fleſhy heads of the oppoſite ſides croſs each other, to form,

s, The

s, A paſſage for the œſophagus.

t, The origin of the diaphragm from the twelfth rib.

u, The pſoas parvus.

v, *v*, The pſoas magnus.

w, The iliacus internus.

x, A ſection of the penis, in which the corpora cavernoſa appear.

FIG. 2.

A View of the Inner Surface of the STERNO-COSTALIS *MUSCLE.*

a, *a*, The tendinous origin, from the cartilago enſiformis and under half of the middle bone of the ſternum.

b, *b*, The tendinous inſertion into the third, fourth, and fifth ribs.

c, Part of the ſterno-coſtalis, paſſing between the ſecond and third ribs, and which is found in ſome ſubjects only.

FIG. 3.

MUSCLES about the Root of the PENIS, *and Under End of the* INTESTINUM RECTUM,—*in a Child.*

a, *a*, The ſphincter ani.

b, The levator ani.

c, The tranſverſalis perinei.

d, The erector penis.

e, The accelerator urinæ.

f, The corpus cavernoſum penis.

g, The corpus ſpongioſum urethræ.

h, The ſcrotum turned up.

i, Part of the thigh.

k, The cut edge of the integuments.

TAB: X.

TABLE X.

REPRESENTS the Firſt Layer of MUSCLES on the Right, and Second Layer of MUSCLES on the Left Side of the Back-Part of the TRUNK of the BODY.

RIGHT SIDE.

a, a, The thoracic portion of the trapezius.
b, b, Its inſertion into the ſpine of the ſcapula.
c, The ligamentum Nuchæ.
d, d, The latiſſimus dorſi.
e, Its tendinous origin.
f, Part of the obliquus externus abdominis.
g, Part of the rhomboideus.

LEFT SIDE.

h, The rhomboides major, and,
i, The rhomboides minor, covering the ſerratus poſticus ſuperior.
k, The ſerratus poſticus inferior.
l, The part from which the latiſſimus dorſi was cut.
m, The under part of the ſerratus magnus.
n, The tendons of the ſacro-lumbalis.
o, A portion of the longiſſimus dorſi.
p, Part of the ſemi-ſpinalis dorſi.
q, The ſpinalis dorſi.
r, The broad tendon common to the latiſſimus dorſi and ſerratus poſticus inferior.
s, The back-part of the obliquus internus abdominis.
t, t, The intercoſtales externi.
u, The coccygeus.
v, The levator ani.
w, The ſphincter ani.

TAB. XI.

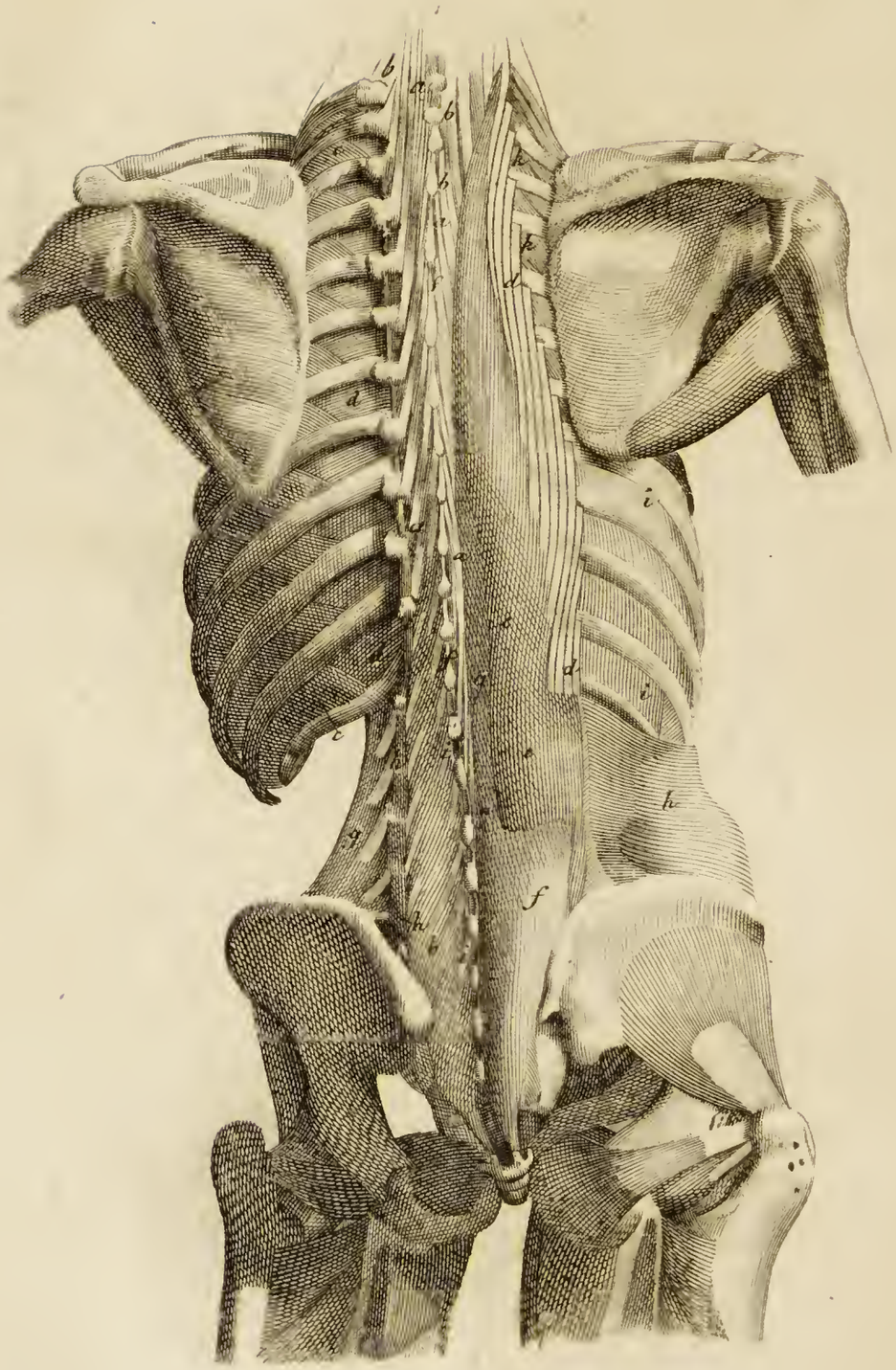

TABLE XI.

REPRESENTS the Third Layer of MUSCLES on the Right, and Fourth Layer of MUSCLES on the Left Side of the Back-part of the TRUNK of the Body.

RIGHT SIDE.

a, a, a, The ſpinalis dorſi.

b, b, Part of the ſemi-ſpinalis dorſi.

c, The longiſſimus dorſi.

d, d, The tendons of the ſacro-lumbalis.

e, The common fleſhy head of the longiſſimus dorſi and ſacro-lumbalis.

f, Tendon covering and partly giving origin to this fleſhy head.

g, Part of this tendon upon the longiſſimus dorſi.

h, The tranſverſalis abdominis.

i, i, The intercoſtales externi.

k, k, Portions of the intercoſtales externi, called by ALBINUS, *Levatores Coſtarum.*

LEFT SIDE.

a, a, The ſemi-ſpinalis dorſi.

b, b, The multifidus ſpinæ.

c, c, The intercoſtales interni.

d, d, The pleura.

e, e, The intertranſverſales dorſi.

f, f, Interſpinales dorſi.

g, Quadratus lumborum.

h, h, Intertranſverſales lumborum.

i, i, Interſpinales lumborum.

TAB. XII.

Fig. 1.

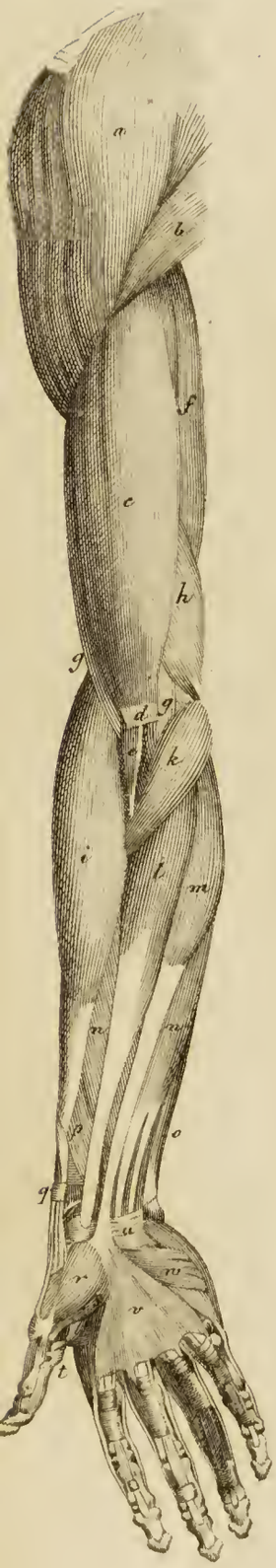

Fig. 2.

Fig. 3.

Fig. 4.

TABLE XII.

REPRESENTS the MUSCLES ſituated on the FORE-PART of the SUPERIOR EXTREMITY.

FIG. I.

A View of the Firſt Layer of MUSCLES on the Fore-part of the SUPERIOR EXTREMITY, the Integuments and Aponeuroſis being removed.

a, The deltoides.

b, The inſertion of the pectoralis major.

c, The biceps flexor cubiti.

d, The aponeuroſis of the biceps cut off.

e, The round tendon of the biceps.

f, The long head of the triceps extenſor cubiti.

g, *g*, The brachialis internus.

h, The third head of the triceps, called *Brachialis Externus*.

i, The ſupinator radii longus.

k, The pronator radii teres.

l, The flexor carpi radialis.

m, Palmaris longus.

n, *n*, Part of the flexor digitorum ſublimis.

o, The under end of the flexor carpi ulnaris.

p, Part of the flexor longus pollicis.

q, The tendons of the extenſores oſſis metacarpi et primi internodii pollicis, with their annular ligament.

r, Abductor pollicis, at the outer edge of which is a ſmall portion of the flexor oſſis metacarpi pollicis.

s, That portion of the abductor pollicis, called by ALBINUS *Abductor Brevis Alter*.

t, Tendon of the flexor longus pollicis, bound by a ligament.

u, The ligamentum carpi annulare anterius.

v, The aponeurosis palmaris, extending from the annular ligament of the wrist to the transverse ligaments at the roots of the fingers, and the adjacent edges of the metacarpal bones.

w, The palmaris brevis, covering part of the abductor, and flexor parvus minimi digiti.

Upon the fingers are seen the annular ligaments retaining the tendons of the flexor sublimis, and flexor profundus, in their places.

FIG. 2.

The Second Layer of MUSCLES *on the Fore-part of the* SUPERIOR EXTREMITY.

a, The biceps flexor cubiti.

b, Its long head.

c, Its short head.

d, A section of the aponeurotic tendon of the biceps.

e, The round tendon of the biceps.

f, Part of the coraco-brachialis.

g, The subscapularis.

h, The teres major.

i, The long head of the triceps extensor cubiti.

k, Its short head.

l, The brachialis externus of the triceps.

m, *m*, The brachialis internus.

n, The extensor carpi radialis longior.

o, The extensor carpi radialis brevior.

p, The supinator radii brevis.

q, Insertion of the flexor carpi ulnaris.

r, The

r, The flexor digitorum ſublimis; its tendons dividing near their inſertion in the ſecond phalanx of the bones of the fingers, for the paſſage of the tendons of the flexor profundus.

s, The extenſor oſſis metacarpi and extenſor primi internodii pollicis.

t, Part of the flexor pollicis longus.

u, Its tendon.

v, The ligamentum carpi annulare.

w, The flexor oſſis metacarpi pollicis.

x, The abductor pollicis brevis alter of ALBINUS.

y, Part of the flexor brevis pollicis.

z, Part of the adductor pollicis.

, The abductor indicis.

2, The abductor minimi digiti.

3, The flexor parvus minimi digiti.

4, 4, The four lumbricales.

FIG. 3.

The Third Layer of MUSCLES on the Fore-Part of the SUPERIOR EXTREMITY.

a, The ſubſcapularis;

b, Its tendon.

c, The teres major;

d, Its tendon.

e, The coraco-brachialis.

f, The brachialis internus.

g, The brachialis externus of the triceps.

h, The extenſor carpi radialis longior.

i, Part

i, Part of the extenſor carpi radialis brevior.

k, The ſupinator radii brevis.

l, The flexor digitorum profundus.

m, The tendons of that muſcle paſſing under the ligamentum carpi annulare, to be inſerted into the third phalanx of the fingers.

n, The ligamentum carpi annulare.

o, *o*, The four lumbricales.

p, The flexor longus pollicis.

q, A ſlip which it ſometimes receives from the inner condyle of the os humeri.

r, The tendon of the flexor longus pollicis inſerted into the laſt joint of the thumb.

s, The flexor brevis pollicis.

t, The firſt interoſſeous muſcle of the fore-finger.

u, The adductor minimi digiti.

FIG. 4.

The Fourth Layer of MUSCLES *on the Fore-part of the* SUPERIOR EXTREMITY.

a, The ſubſcapularis.

b, The ſupinator radii brevis.

c, The pronator radii quadratus.

d, The flexor brevis pollicis, with its inſertion into the oſſa ſeſamoidea.

e, The adductor pollicis.

f, *f*, The ſeven interoſſei,—the firſt placed at the outer ſide of the metacarpal bone of the fore-finger,—the reſt of them between the metacarpal bones.

TAB. XIII.

Fig. 1.

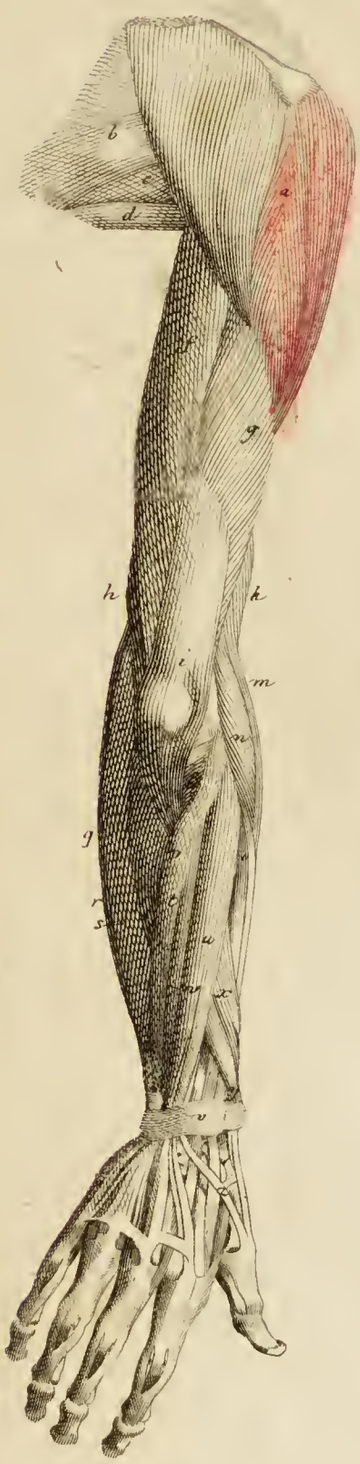

Fig. 3.

Fig. 2.

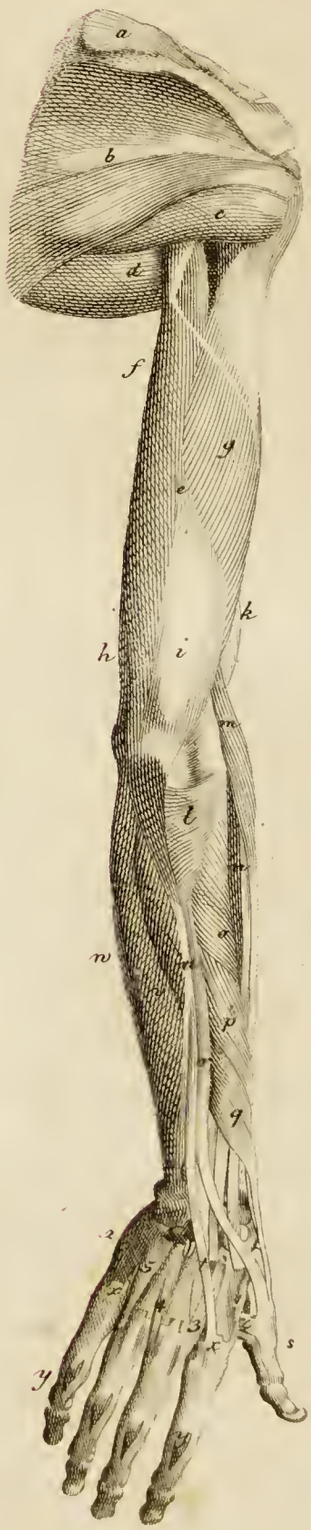

Fig. 4.

TABLE XIII.

REPRESENTS the MUSCLES on the Back-Part of the SUPERIOR EXTREMITY.

FIG. 1.

A View of the First Layer of MUSCLES on the Back-Part of the SUPERIOR EXTREMITY.

a, The deltoides, with its insertion into the os humeri.
b, The infra-spinatus.
c, The teres minor.
d, The teres major.
e, The triceps extensor cubiti.
f, The long, and,
g, The short head of the triceps.
h, The third head, called *brachialis externus.*
i, The common tendon of the three heads.
k, Part of the brachialis internus.
l, Part of the anconeus.
m, The supinator radii longus.
n, The extensor carpi radialis longior.
o, The extensor carpi radialis brevior.
p, Part of the flexor profundus, which comes from the ulna.
q, Part of the palmaris longus.
r, Part of the flexor digitorum sublimis.
s, The flexor carpi ulnaris.
t, The extensor carpi ulnaris.
u, Extensor digitorum communis, in which are seen,
Its passage under *v*, the ligamentum carpi annulare posterius;
The portion *w*, which it sends to the little finger;
Its flat tendons, running along the metacarpal bones;
The aponeurotic slips, which join these tendons together near the first joint of the fingers;
The tendons upon the back of the fingers, forming broad expansions

panſions which cover and adhere to the firſt and ſecond, and are inſerted into the baſe of the third, phalanges;

The ſplitting and rejoining of the tendons, between the firſt and ſecond phalanges, for facilitating the motion of the joints.

x, The extenſor oſſis metacarpi, and, *y*, The extenſor primi internodii pollicis, with their annular ligament.

z, The tendon of the extenſor ſecundi internodii pollicis.

FIG. 2.

The Second Layer of MUSCLES *on the Back-Part of the* SUPERIOR EXTREMITY.

a, The ſupra-ſpinatus.

b, The infra-ſpinatus.

c, The teres minor.

d, The teres major.

e, The triceps extenſor cubiti.

f, Its long head.

g, Its ſhort head.

h, Part of the third head, named *brachialis externus*.

i, The common tendon of the triceps inſerted into the olecranon.

k, Part of the brachialis internus.

l, The anconeus.

m, The extenſor carpi radialis longior.

n, The extenſor carpi radialis brevior.

o, The ſupinator radii brevis.

p, The extenſor oſſis metacarpi pollicis.

q, The extenſor primi internodii pollicis.

r, The extenſor ſecundi internodii pollicis.

s, The conjoined tendons of the three extenſors of the thumb.

t, The indicator.

u, The flexor digitorum profundus.

v, The

v, The flexor carpi ulnaris.

w, A ſmall portion of the flexor ſublimis.

x, *x*, The cut tendons of the extenſor digitorum communis.

y, *y*, Tendinous ſlips of the extenſor communis, fixed to the ſecond phalanx.

z, The adductor pollicis.

1, The abductor indicis.

2, The abductor minimi digiti.

The poſterior interoſſei, conſiſting of, 3, The prior medii digiti, 4, Poſterior medii digiti, and, 5, Poſterior annularis.

FIG. 3.

The Third Layer of MUSCLES *upon the Back-Part of the* SUPERIOR EXTREMITY.

a, The teres major.

b, Part of the ſubſcapularis.

c, Part of the coraco-brachialis.

d, Part of the brachialis internus.

e, The brachialis externus.

f, The extenſor carpi radialis longior.

g, The extenſor carpi radialis brevior.

h, The flexor profundus perforans.

i, The ſupinator radii brevis.

k, Part of the flexor longus pollicis.

l, The pronator radii quadratus.

m, *m*, Cut tendons of the extenſor digitorum.

n, Flexor brevis pollicis.

o, Adductor pollicis.

p, *p*, The interoſſei interni, with portions of the interoſſei externi, the reſt of the interoſſei externi being cut off.

At the lateral parts of the roots of the fingers, in this and the

two

two former figures, are ſeen the joining of the tendons of the extenſor digitorum, and of the lumbricales and interoſſei.

FIG. 4.

A Poſterior View of the Fourth Layer of MUSCLES *on the* SUPERIOR EXTREMITY.

a, The ſubſcapularis.

b, The ſupinator radii brevis.

c, The pronator radii quadratus.

d, The flexor brevis pollicis.

e, The adductor pollicis.

TAB. XIV.

Fig. 1.

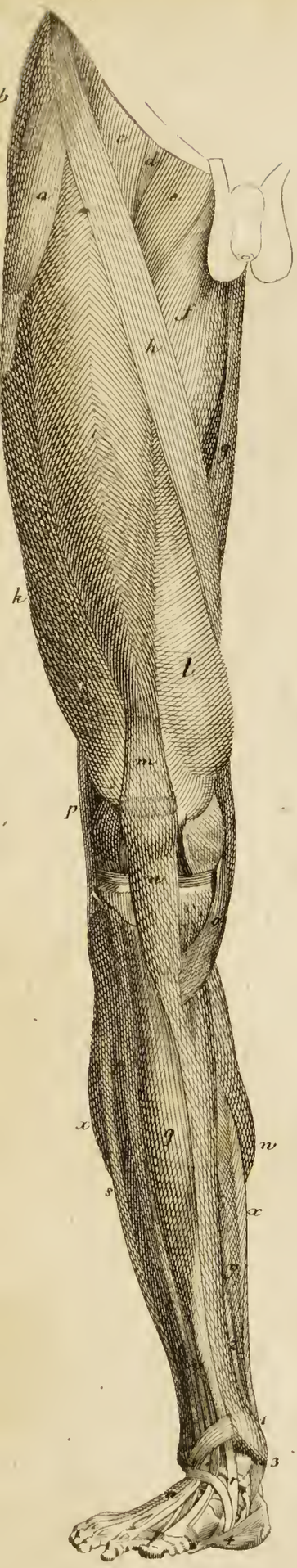

Fig. 2.

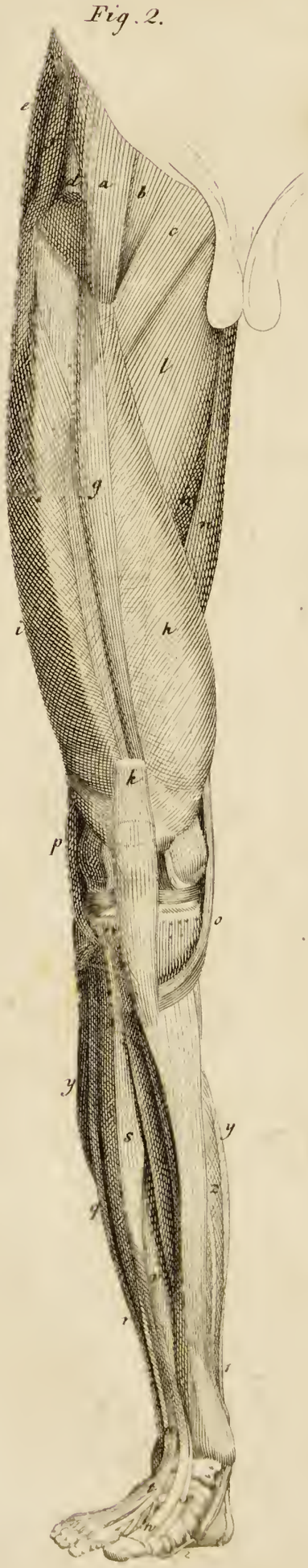

Fig. 3.

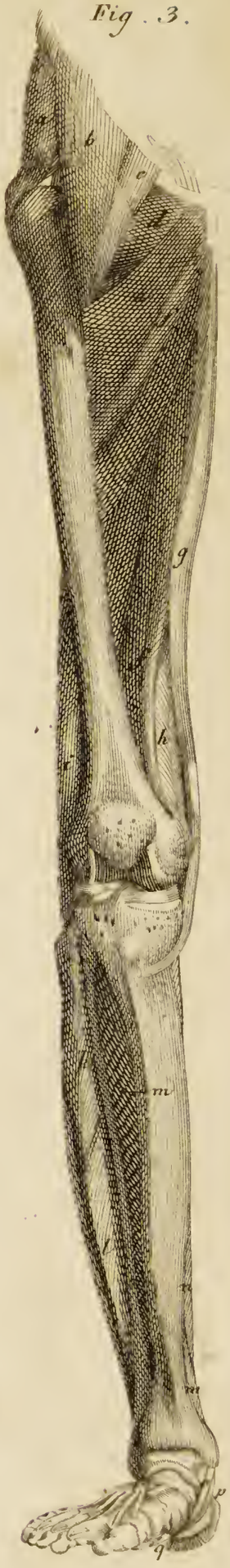

Fig. 4.

TABLE XIV.

REPRESENTS the MUSCLES on the Fore-Part of the INFERIOR EXTREMITY.

FIG. 1.

The First Layer of MUSCLES on the Fore-Part of the INFERIOR EXTREMITY.

a, The tensor vaginæ femoris.
b, The anterior edge of the gluteus medius.
c, The under end of the iliacus internus, and of,
d, The psoas magnus.
e, The pectinalis.
f, The adductor longus femoris.
g, The gracilis.
h, The sartorius.
i, The rectus femoris.
k, The vastus externus.
l, The vastus internus.
m, The ligament common to the extensors of the leg, fixed to the patella.
n, Ligament fixing the patella to the tibia.
o, The tendons of the sartorius, gracilis, and semi-membranosus.
p, The under end of the biceps flexor cruris.
q, The tibialis anticus;
r, Its tendon.
s, The peroneus longus.
t, The extensor longus digitorum pedis.
u, The tendons of the extensor longus.

v, The

v, The extenſor proprius pollicis.
w, The gaſtrocnemius externus.
x, *x*, The gaſtrocnemius internus.
y, The flexor longus digitorum pedis.
z, The tibialis poſticus.
1, The tendo Achillis, and tendon of the plantaris.
2, The upper and under portions of the ligamentum tarſi annulare.
3, Ligaments retaining the tendons at the inner ankle.
4, The abductor pollicis.

FIG. 2.

The Second Layer of MUSCLES *on the Fore-Part of the* SUPERIOR EXTREMITY.

a, The under end of the iliacus internus.
b, The under end of the pſoas magnus.
c, The pectinalis.
d, The cut end of the rectus femoris.
e, The anterior edge of the gluteus medius.
f, The gluteus minimus.
g, The cruralis, with its tendinous faſcia.
h, The vaſtus internus.
i, The vaſtus externus.
k, The cut end of the rectus fixed to the patella.
l, The adductor longus femoris.
m, A ſmall portion of the adductor magnus.
n, The gracilis.
o, The tendons of the gracilis and ſemi-tendinoſus.
p, The tendon of the biceps flexor cruris.
q, The peroneus longus.

r, The

r, The peroneus brevis.

s, The extenſor longus digitorum pedis;

t, The tendons of that muſcle.

u, The peroneus tertius.

v, The extenſor proprius pollicis;

w, Its tendon;

x, A branch of that tendon not conſtant.

y, *y*, The edges of the gaſtrocnemius internus.

z, The edge of the flexor longus digitorum pedis.

1, The tendons of the tibialis poſticus and flexor longus digitorum.

2, Part of the flexor brevis digitorum.

FIG. 3.

The Third Layer of MUSCLES *on the Fore-part of the* INFERIOR EXTREMITY.

a, The gluteus minimus.

b, The iliacus internus.

c, The pſoas magnus.

d, The obturator externus.

e, The adductor brevis.

f, *f*, The adductor magnus.

g, The gracilis.

h, The ſemi-membranoſus, with its inſertion in the tibia.

i, The ſhort head of the biceps flexor cruris.

k, The peroneus longus.

l, The peroneus brevis.

m, *m*, The tibialis poſticus, the interoſſeous ligament being removed.

n, The flexor longus digitorum pedis.

o, The tendon of the tibialis poſticus.

p, The tendon of the flexor longus digitorum.

 q, The

q, The tendon of the flexor longus pollicis pedis.
r, The extenſor brevis digitorum pedis.

FIG. 4.

An Anterior View of the Fourth Layer of MUSCLES *on the* INFERIOR EXTREMITY.

a, The pſoas magnus.
b, The iliacus internus.
c, The obturator externus.
d, *d*, The adductor magnus.
e, The tibialis poſticus;
f, Its tendon.
g, The peroneus brevis.
h, The interoſſei externi.

Tab. XV.

Fig. 1.

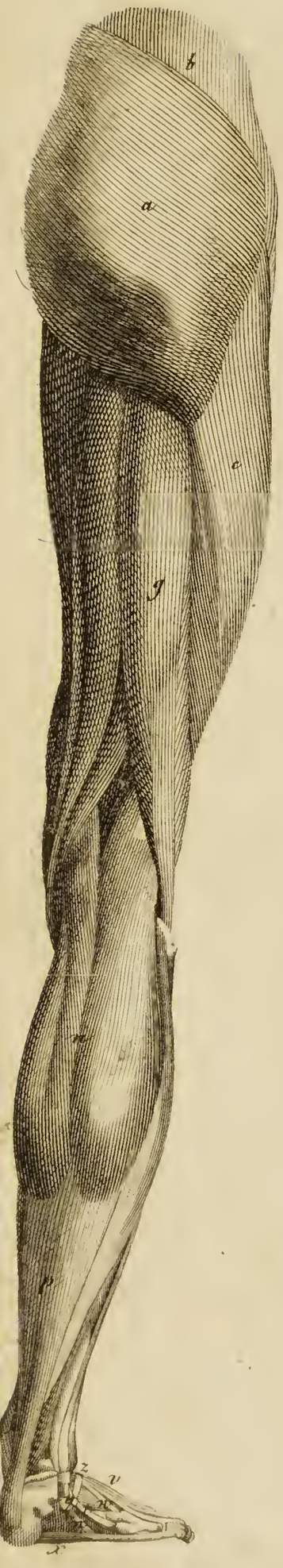

Fig. 2.

Fig. 3.

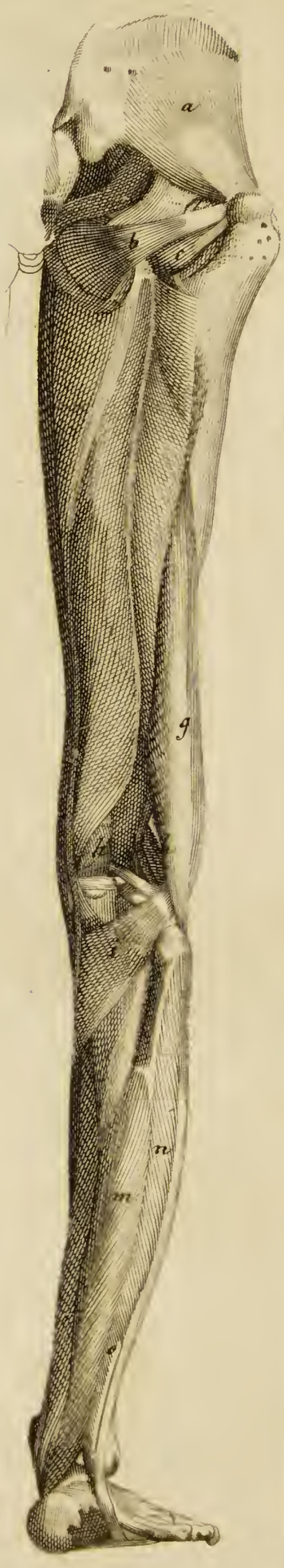

Fig. 4.

Fig. 5.

Fig. 6.

TABLE XV.

Represents the Muscles ſituated on the Back-Part of the Inferior Extremity.

FIG. 1.

A View of the Firſt Layer of Muscles on the Back-part of the Inferior Extremity.

a, The gluteus maximus.
b, Part of the gluteus medius.
c, The vaſtus externus.
d, Part of the adductor magnus femoris.
e, The gracilis.
f, Part of the ſartorius.
g, The long head of the biceps flexor cruris;
h, Its ſhort head.
i, The ſemi-tendinoſus.
k, The ſemi-membranoſus.
l, Part of the vaſtus internus.
m, The edge of the plantaris.
n, The gaſtrocnemius externus.
o, *o*, The edges of the gaſtrocnemius internus.
p, The tendo Achillis.
q, The peroneus longus.
r, The peroneus brevis.
s, The flexor longus pollicis pedis.
t, The tendon of the peroneus brevis.
u, The tendon of the peroneus longus, in its paſſage to the ſole.

v, The

v, The tendons of the extenſor longus digitorum pedis.

w, The tendon of the peroneus tertius.

x, The abductor minimi digiti pedis.

y, A ligament common to the long and ſhort peronei muſcles, and one proper to each of them.

z, The ligamentum tarſi annulare.

FIG. 2.

The Second Layer of MUSCLES *on the Back-part of the* INFERIOR EXTREMITY.

a, The gluteus medius.

b, The pyriformis.

c, The gemini.

d, The tendon of the obturator internus paſſing between the gemini.

e, The quadratus femoris.

f, The vaſtus externus.

g, The adductor magnus femoris.

h, The ſemi-tendinoſus.

i, The gracilis.

k, The ſemi-membranoſus.

l, The biceps flexor cruris.

m, The long head of the biceps.

n, The ſhort head.

o, The common tendon of the two heads.

p, Part of the vaſtus internus.

q, *q*, The cut heads of the gaſtrocnemius externus.

r, The popliteus.

s, The ſoleus.

t, The

t, The plantaris.

u, The cut tendon of the gaſtrocnemius externus.

v, The tendo Achillis, with the tendon of the plantaris adhering to it.

w, The peroneus longus.

x, The peroneus brevis.

y, The flexor pollicis longus.

z, The tendons of the extenſor digitorum longus.

1, The extenſor brevis digitorum.

2, The flexor brevis digitorum.

FIG. 3.

The Third Layer of MUSCLES *on the Back-part of the* INFERIOR EXTREMITY.

a, The gluteus minimus.

b, The obturator internus.

c, The tendon of the obturator externus.

d, The gracilis.

e, The ſemi-membranoſus.

f, *f*, The adductor magnus femoris.

g, The ſhort head of the biceps.

h, *h*, The cut heads of the gaſtrocnemius externus, with a view of the ſemilunar cartilages.

i, The popliteus.

k, The tibialis poſticus.

l, The flexor longus digitorum pedis.

m, The flexor longus pollicis pedis.

n, The

n, The peroneus longus, with the paſſage of its tendon to the ſole.

o, The peroneus brevis.

p, The extenſor brevis digitorum pedis.

q, The flexor digitorum acceſſorius.

FIG. 4.

A Poſterior View of the Fourth Layer of MUSCLES *on the* INFERIOR EXTREMITY.

a, Part of the iliacus internus.

b, Part of the pſoas magnus.

c, Their inſertion into the trochanter minor.

d, The obturator externus.

e, *e*, The adductor magnus femoris.

f, The tibialis poſticus.

g, The peroneus brevis, with the inſertion of its tendon.

FIG. 5.

Repreſents the Firſt Layer of MUSCLES *on the Sole of the Foot, after removing the Common Integuments, the Aponeuroſis Plantaris, and the Vaginal Ligaments of the Toes.*

a, The flexor brevis digitorum, the tendons of which are perforated by the tendons of the flexor longus, and inſerted into the ſecond phalanx of the four ſmall toes.

b, The tendon of the flexor longus pollicis, at the ſides of which the flexor brevis pollicis appears.

c, The abductor pollicis.

d, *d*, The abductor minimi digiti.

e, *e*, The tranſverſalis pedis.

FIG.

TABLE XV. CONTINUED.

FIG. 6.

The MUSCLES *which appear in the Sole, after those represented in the former Figure, have been removed.*

a, The tendon of the flexor longus digitorum.

b, *b*, The flexor digitorum accessorius, with its insertion into the tendon of the flexor longus digitorum.

c, The connection of the flexor longus digitorum, and flexor longus pollicis.

d, *d*, The insertion of the tendons of the flexor longus digitorum into the last phalanx of the four small toes.

e, *e*, *e*, *e*, The four lumbricales.

f, *f*, The tendon of the flexor longus pollicis.

g, The insertion of the tibialis posticus.

h, The insertion of the tibialis anticus.

i, *i*, The two portions of the flexor brevis pollicis.

k, A small portion of the adductor pollicis.

l, The insertion of the peroneus brevis.

m, The tendon of the peroneus longus, passing to the sole.

n, The flexor brevis minimi digiti.

o, *o*, Two of the interossei, the insertions of which, and of the other interossei, are seen at the lateral parts of the roots of the toes.

p, *p*, The transversalis pedis.

J. PILLANS & SONS, PRINTERS,
NORTH COLLEGE-STREET, EDINBURGH.

Rockburn No 64